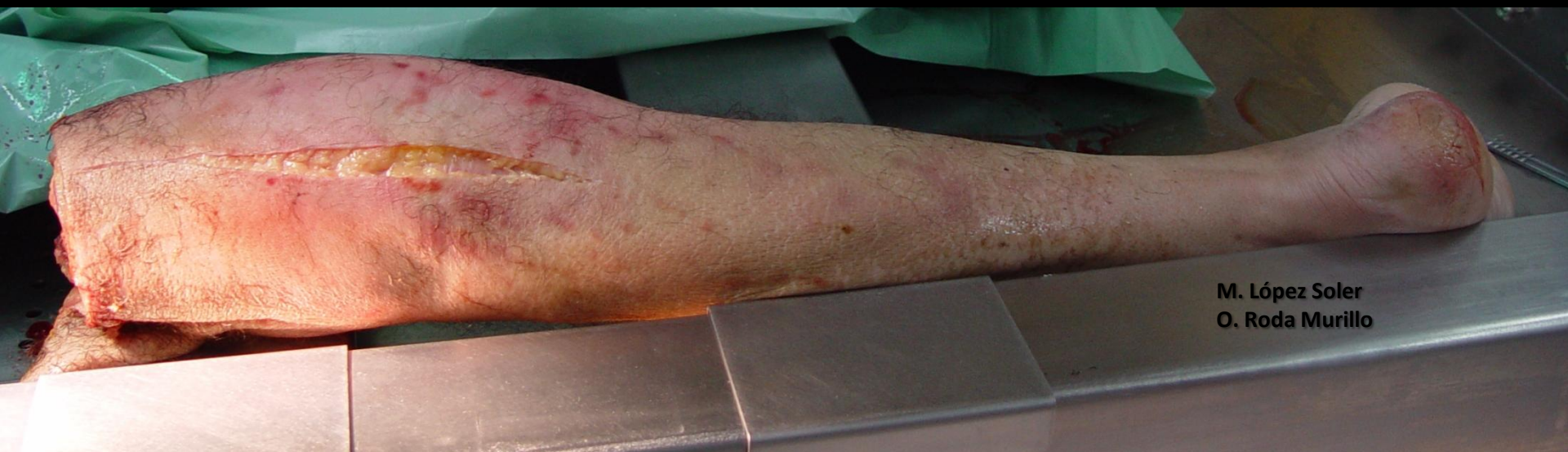

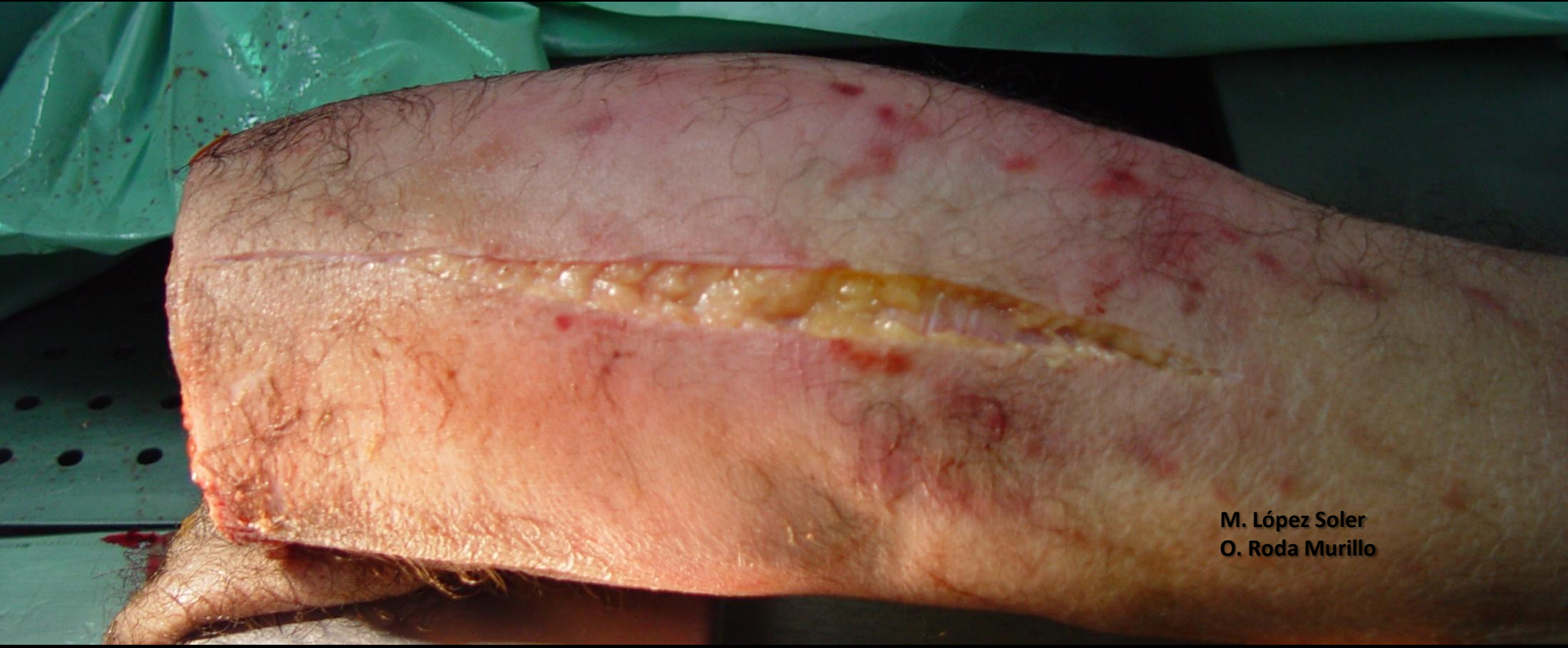NERVIOS TIBIAL Y PERONEO (II)

Disecciones

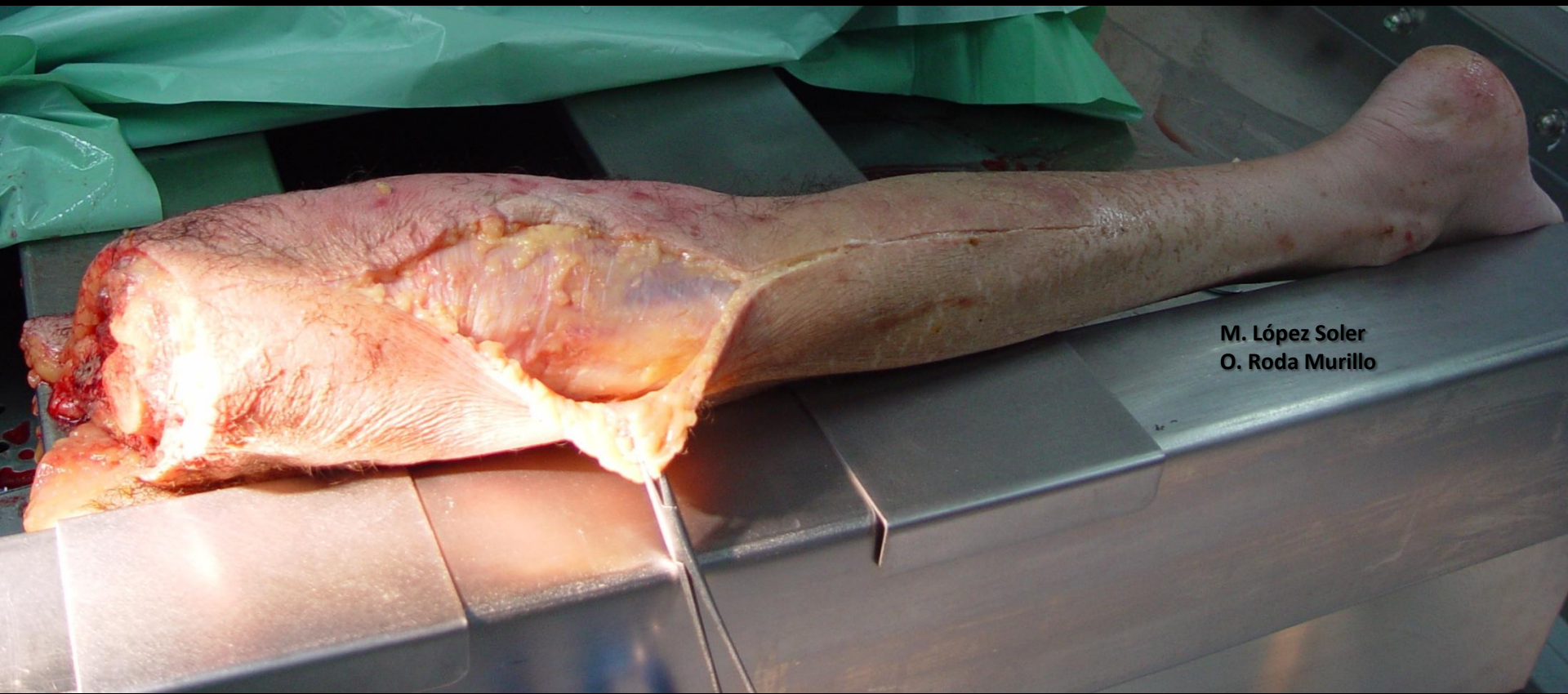M. López Soler
O. Roda Murillo



M. López Soler
O. Roda Murillo



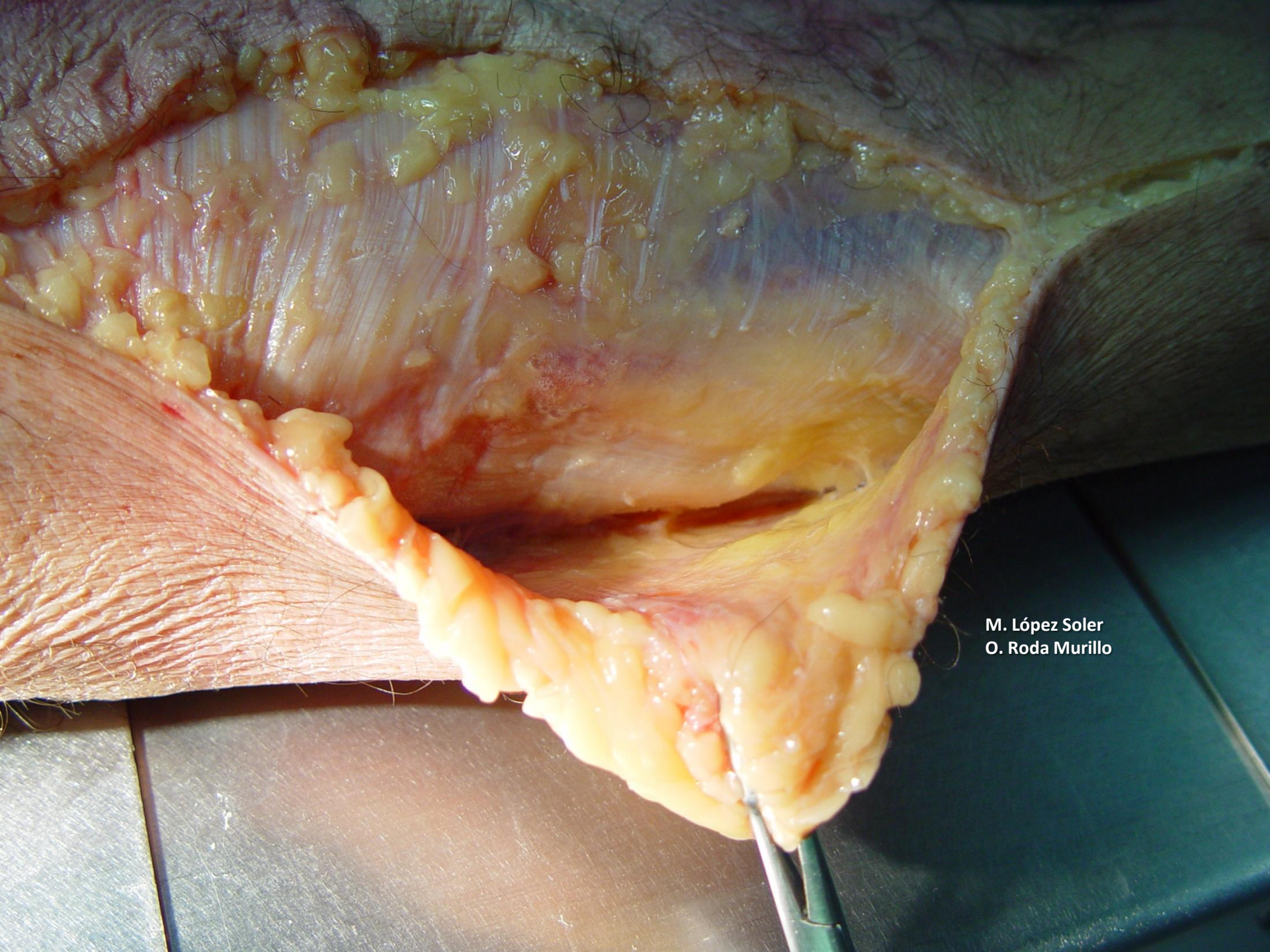
M. López Soler
O. Roda Murillo




M. López Soler
O. Roda Murillo



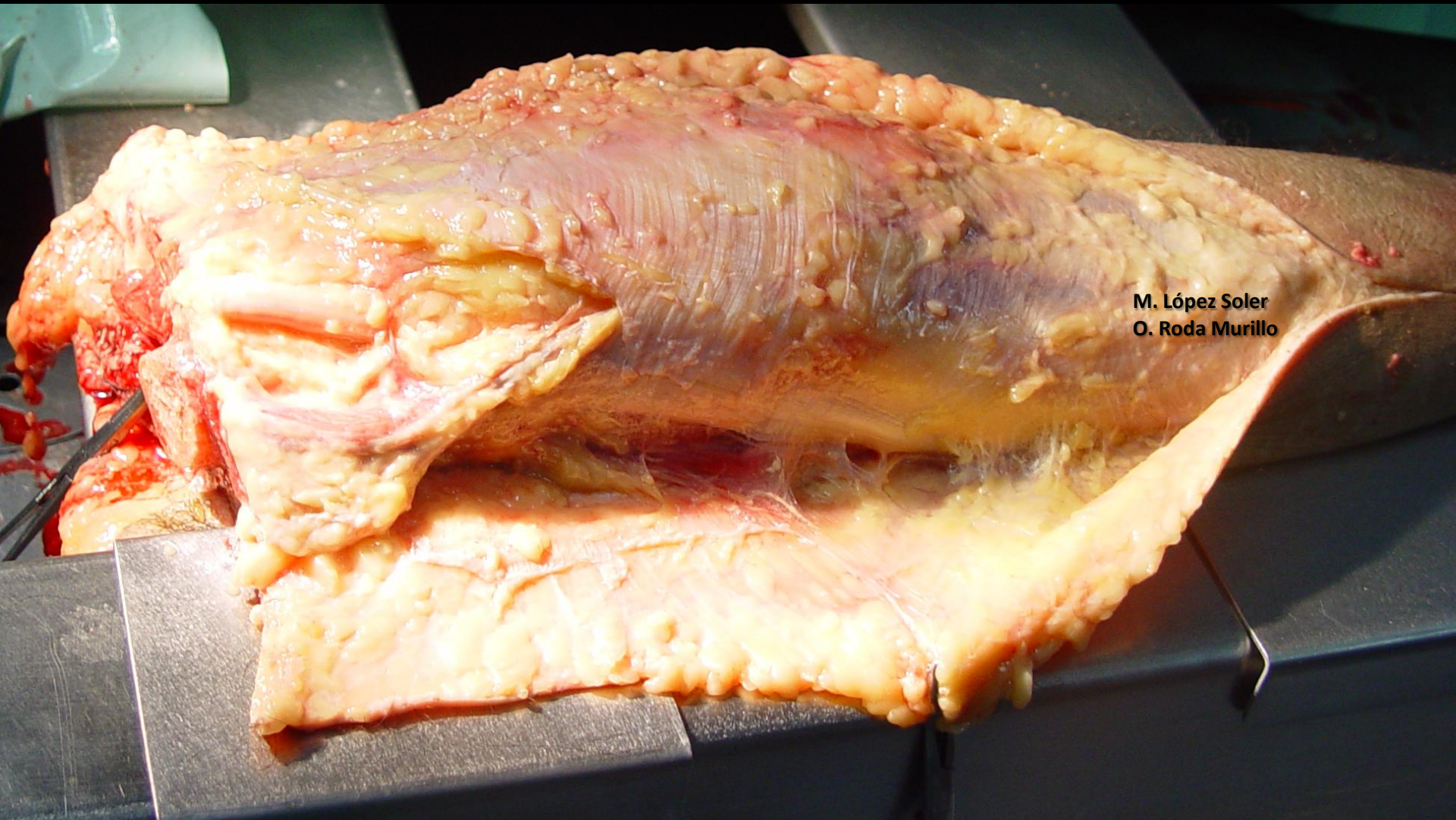
M. López Soler
O. Roda Murillo



M. López Soler
O. Roda Murillo



M. López Soler
O. Roda Murillo



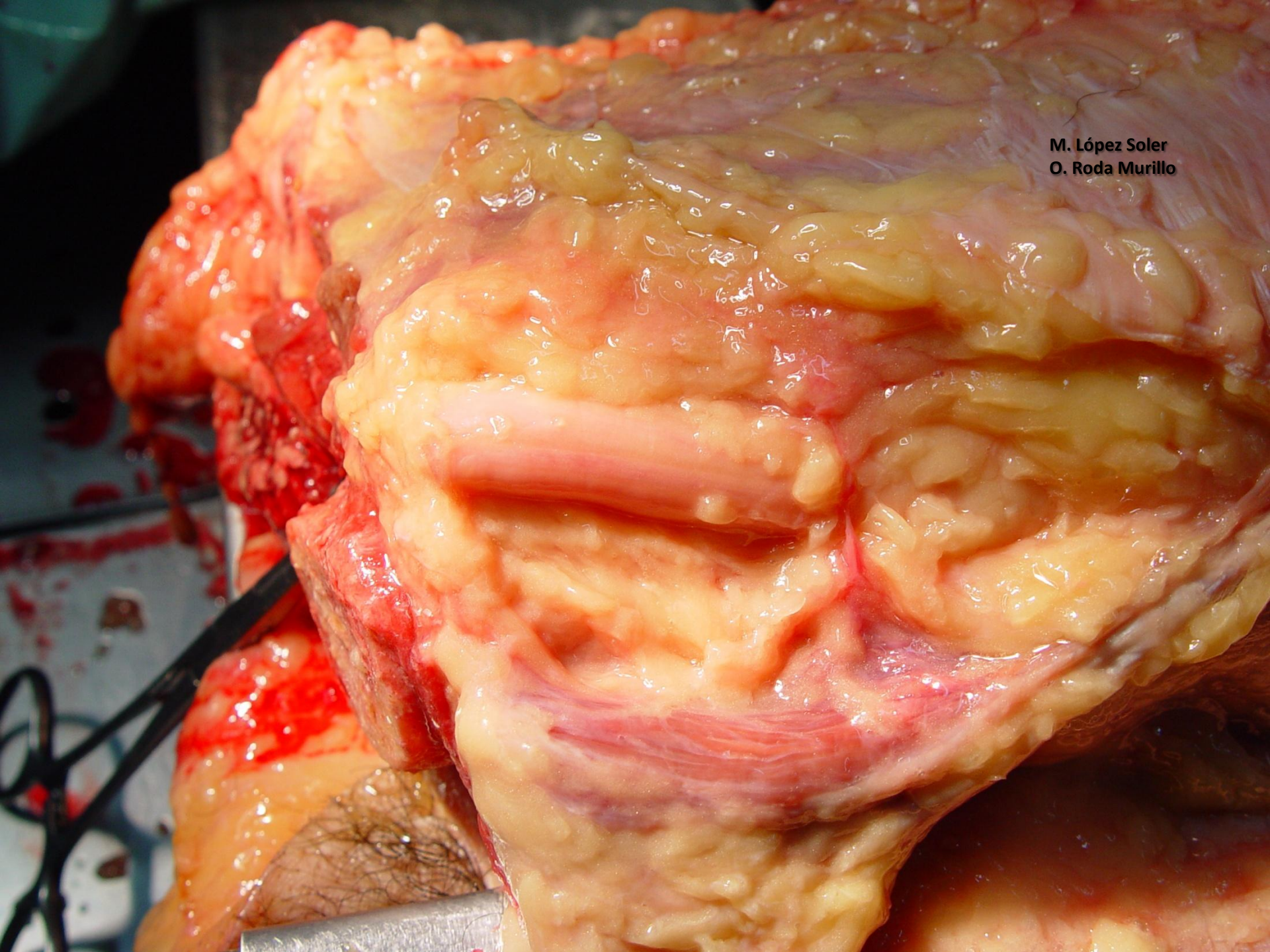
M. López Soler
O. Roda Murillo

**NERVIO
CIÁTICO**




**M. López Soler
O. Roda Murillo**

M. López Soler
O. Roda Murillo




M. López Soler
O. Roda Murillo

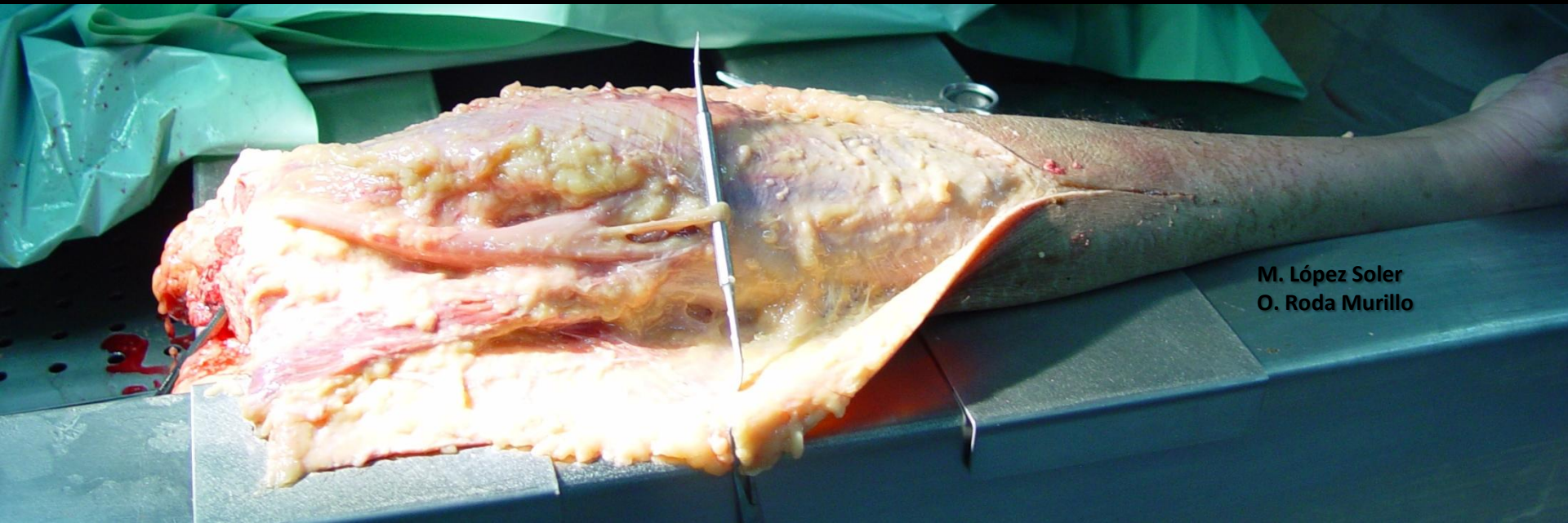
NERVIO
CIÁTICO



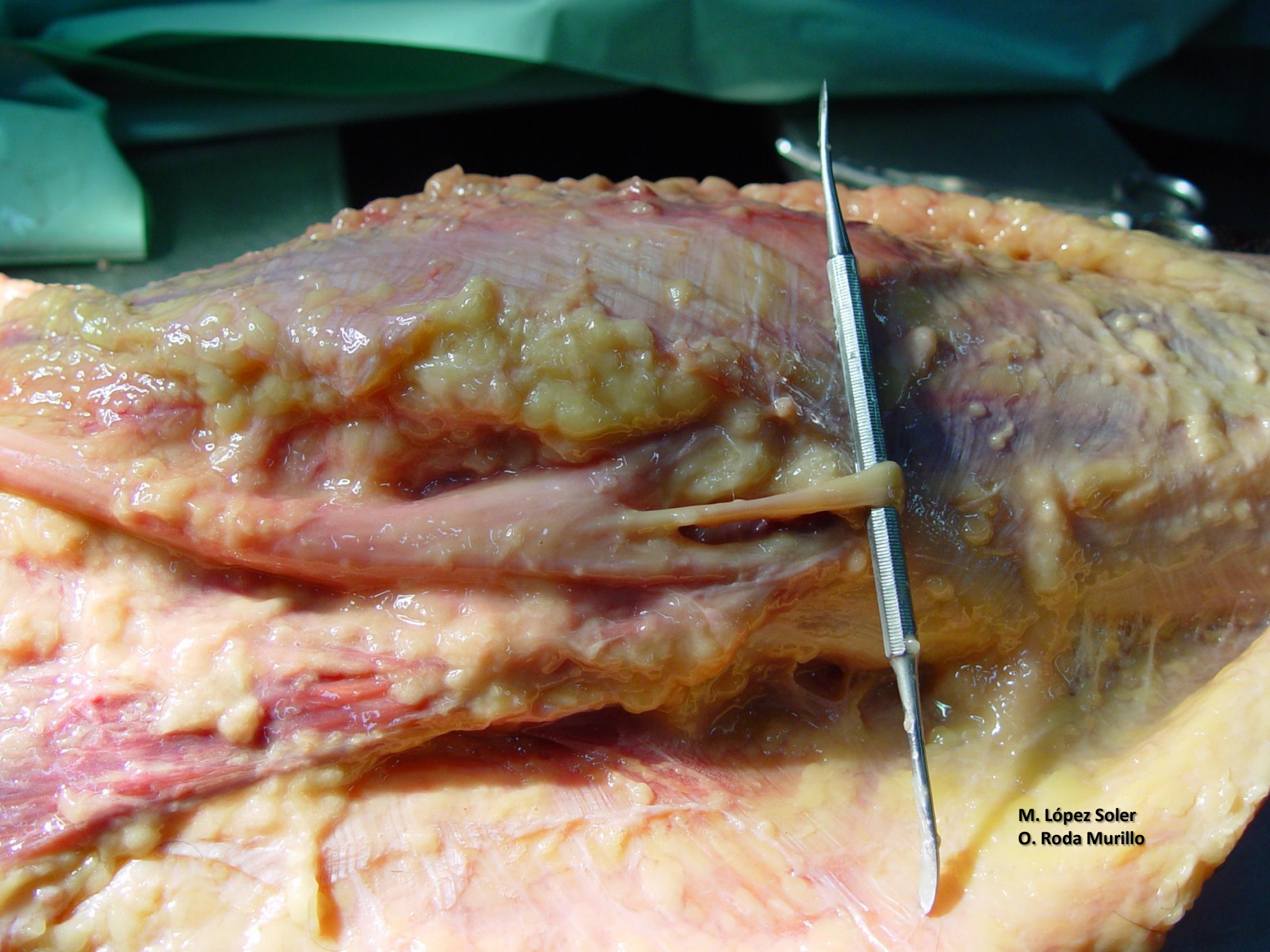
M. López Soler
O. Roda Murillo

NERVIO
CIÁTICO

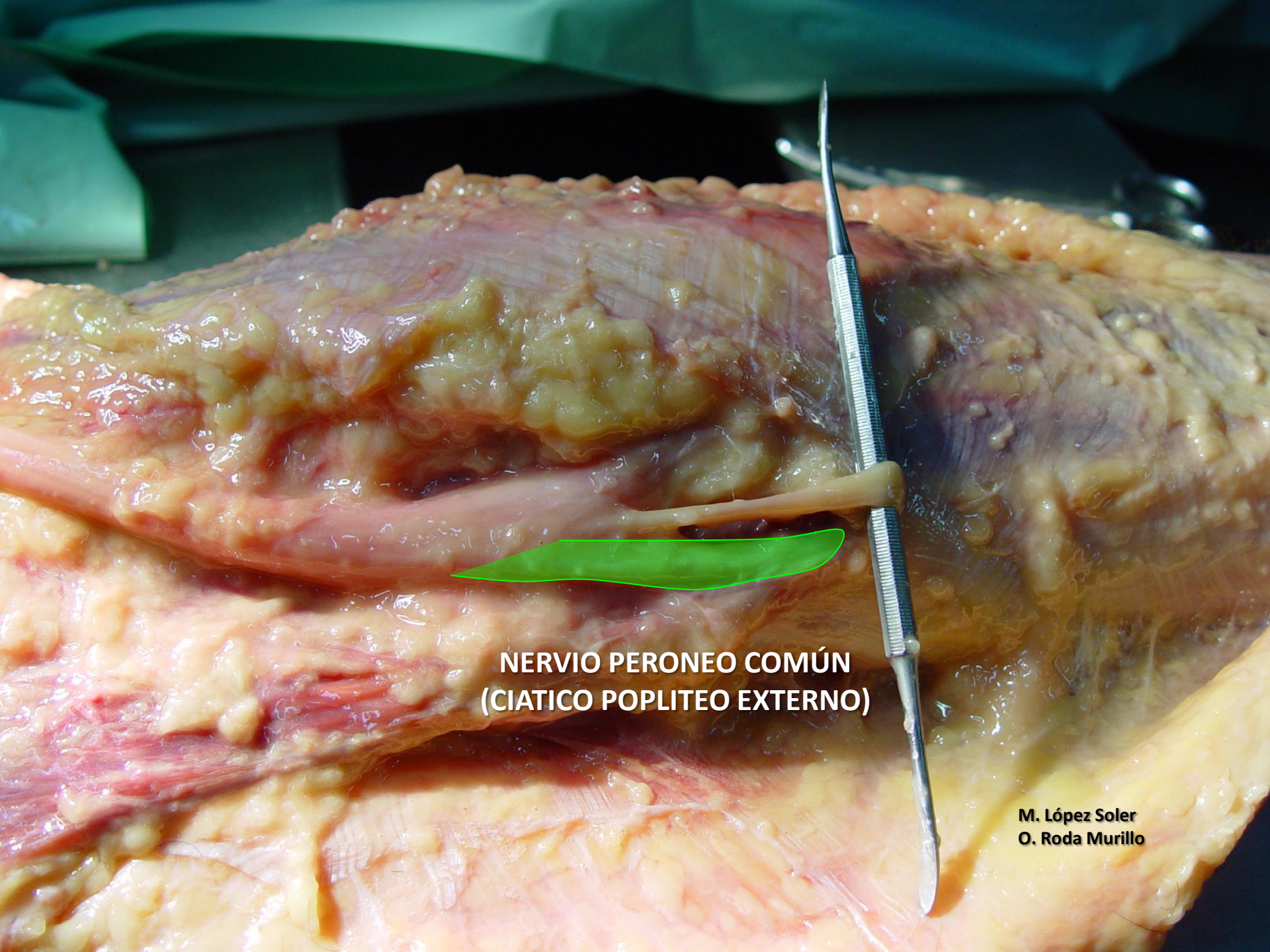




M. López Soler
O. Roda Murillo



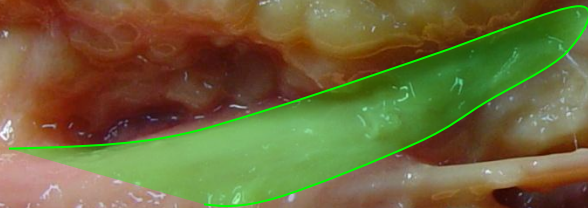
M. López Soler
O. Roda Murillo



**NERVIO PERONEO COMÚN
(CIATICO POPLITEO EXTERNO)**

**M. López Soler
O. Roda Murillo**

**NERVIO TIBIAL
(CIÁTICO POPLÍTEO INTERNO)**

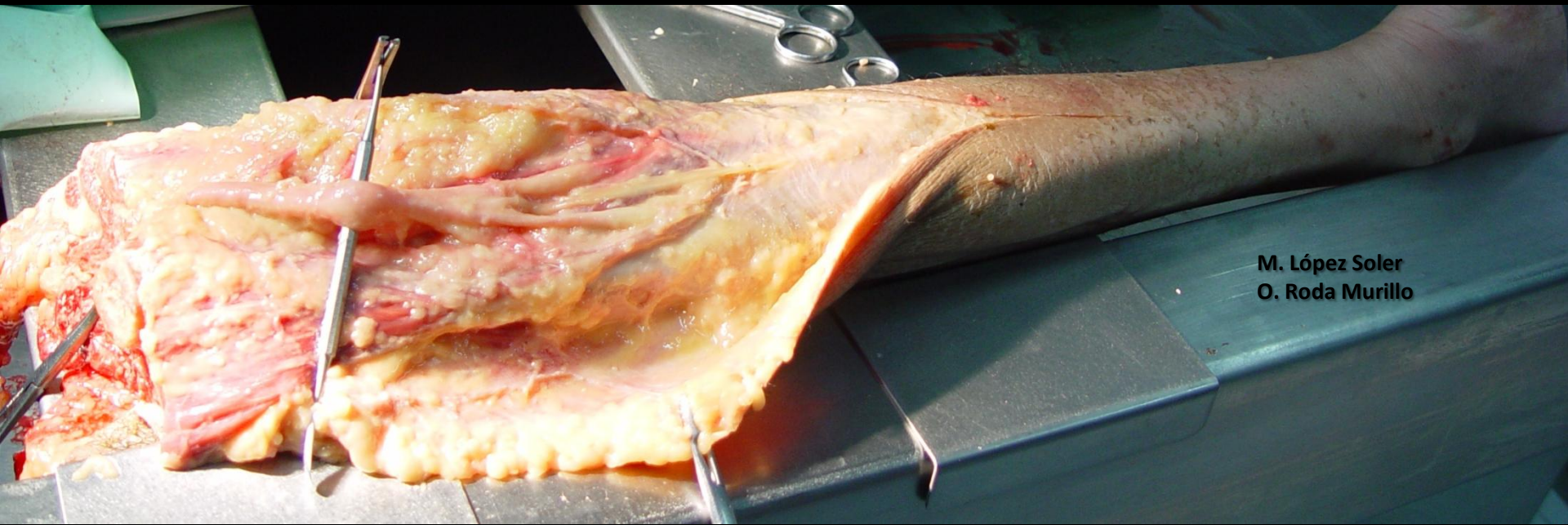


**M. López Soler
O. Roda Murillo**



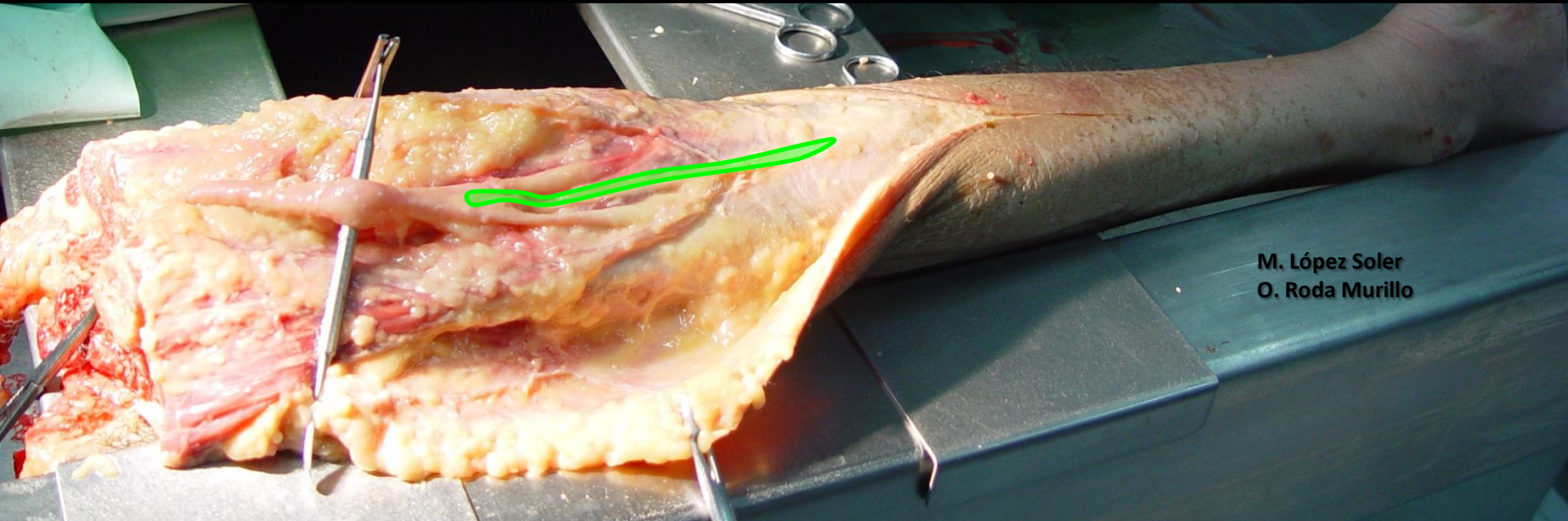
**NERVIO CUTANEO SURAL MEDIAL
(NERVIO SAFENO EXTERNO)**

**M. López Soler
O. Roda Murillo**

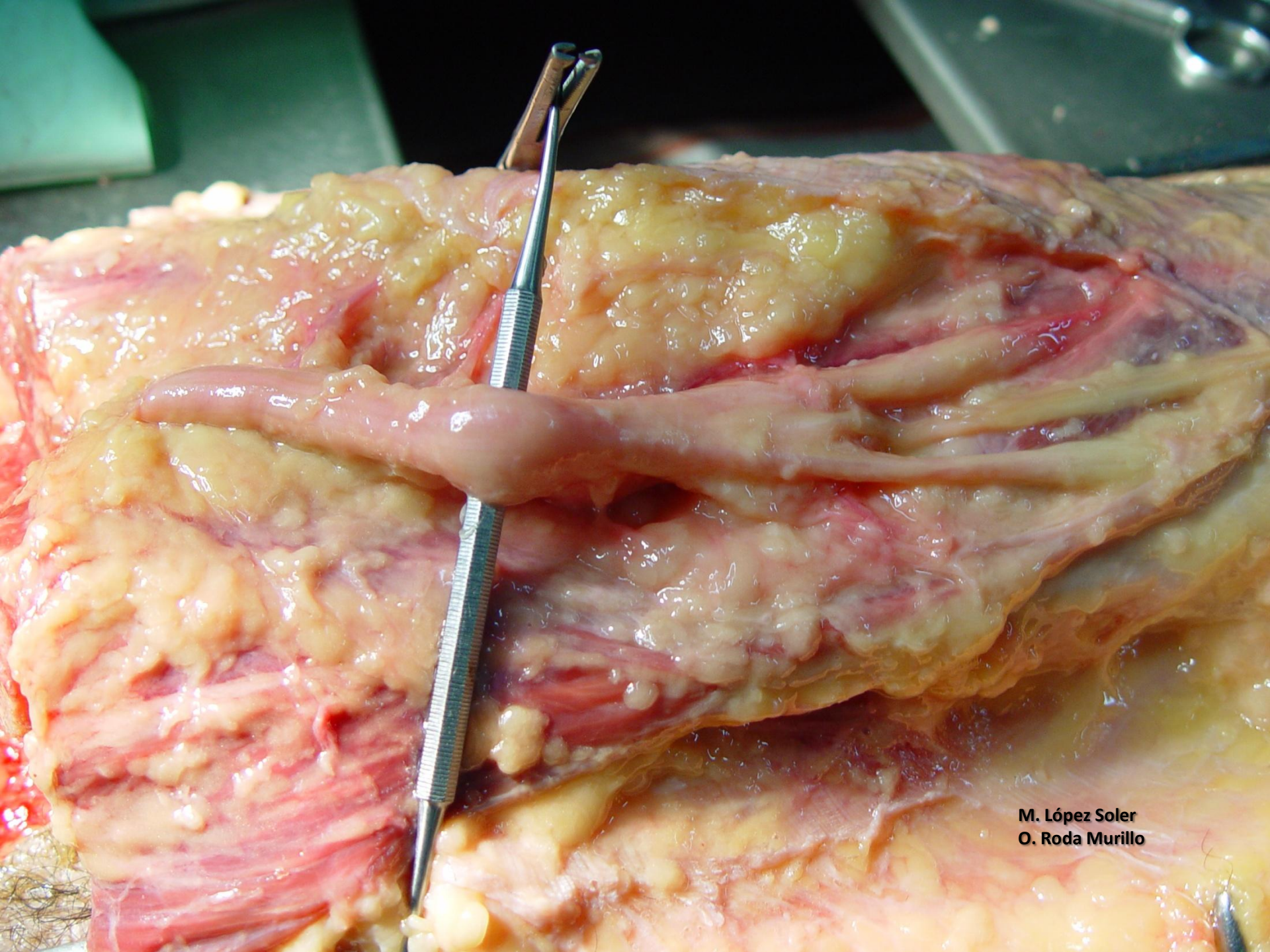


M. López Soler
O. Roda Murillo

**NERVIO CUTANEO SURAL MEDIAL
(NERVIO SAFENO EXTERNO)**

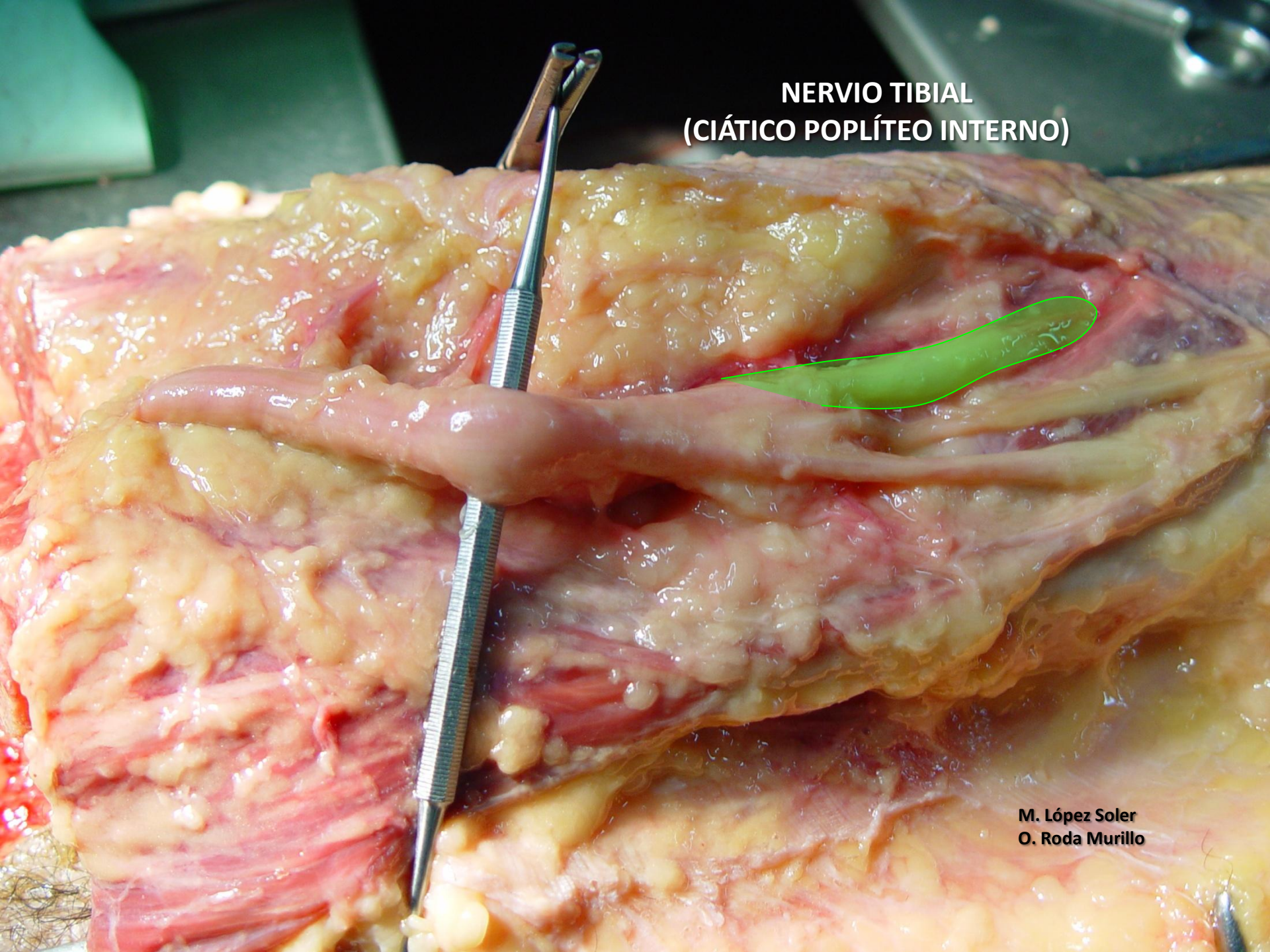


M. López Soler
O. Roda Murillo

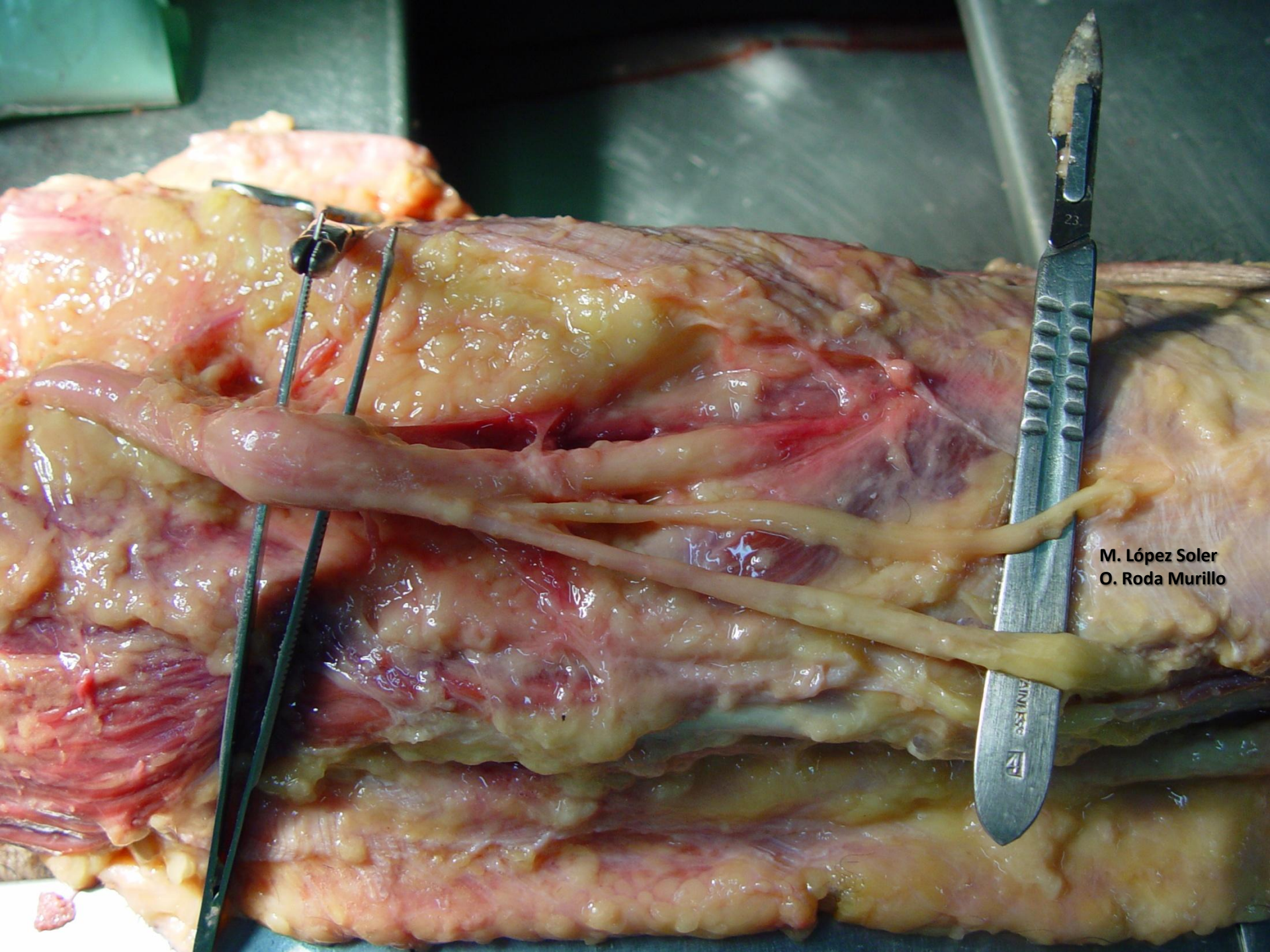


M. López Soler
O. Roda Murillo

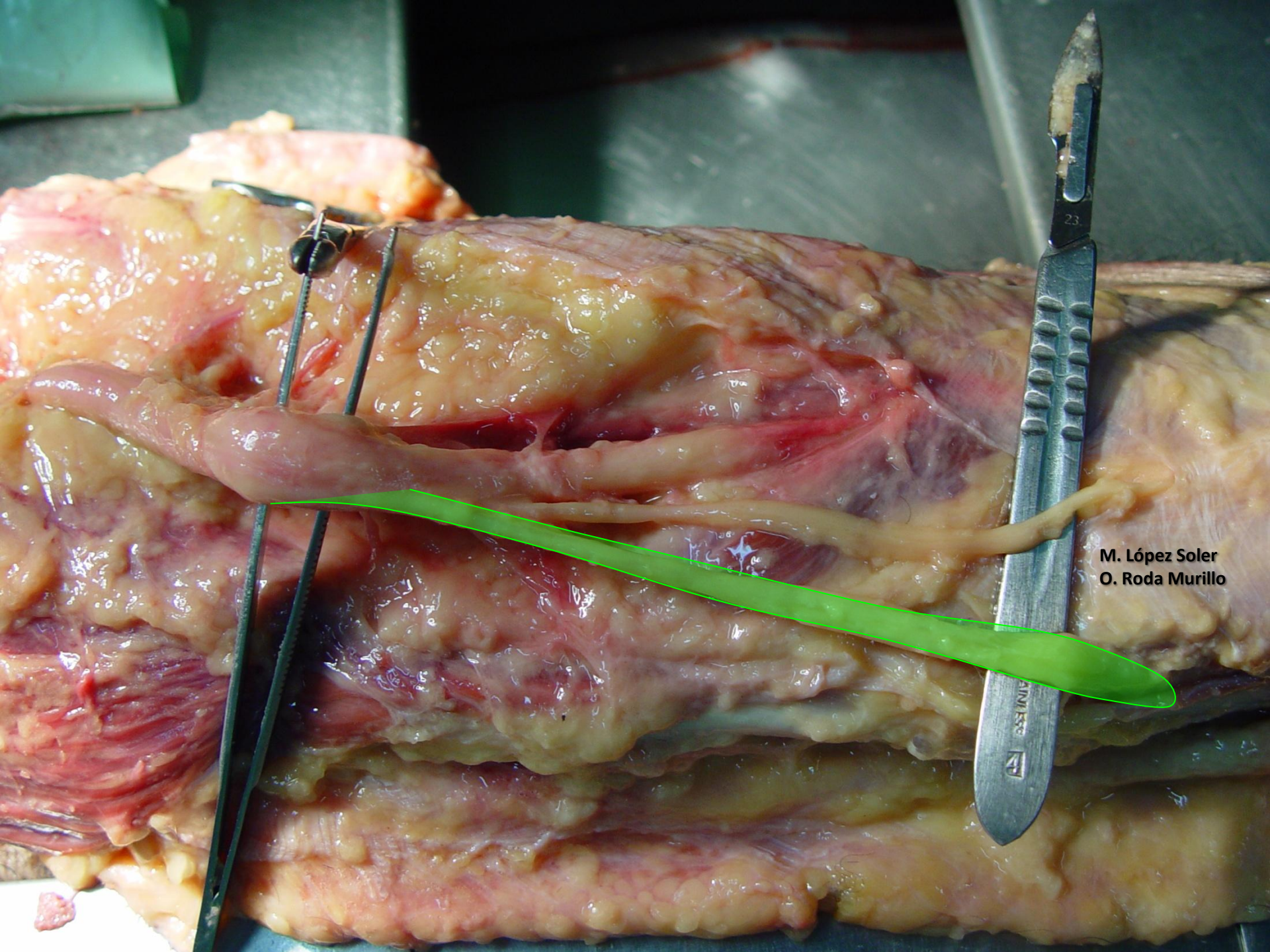
**NERVIO TIBIAL
(CIÁTICO POPLÍTEO INTERNO)**



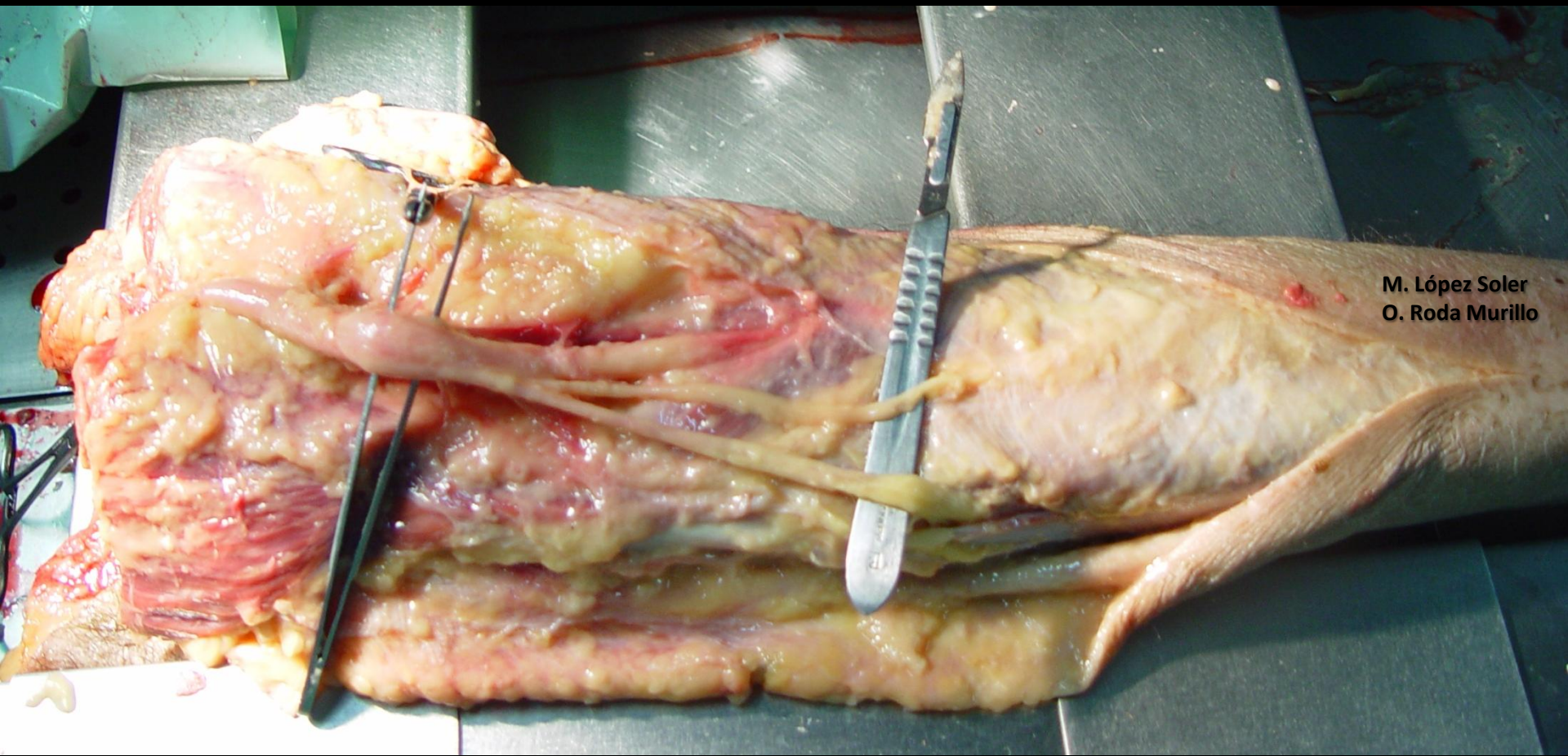
M. López Soler
O. Roda Murillo



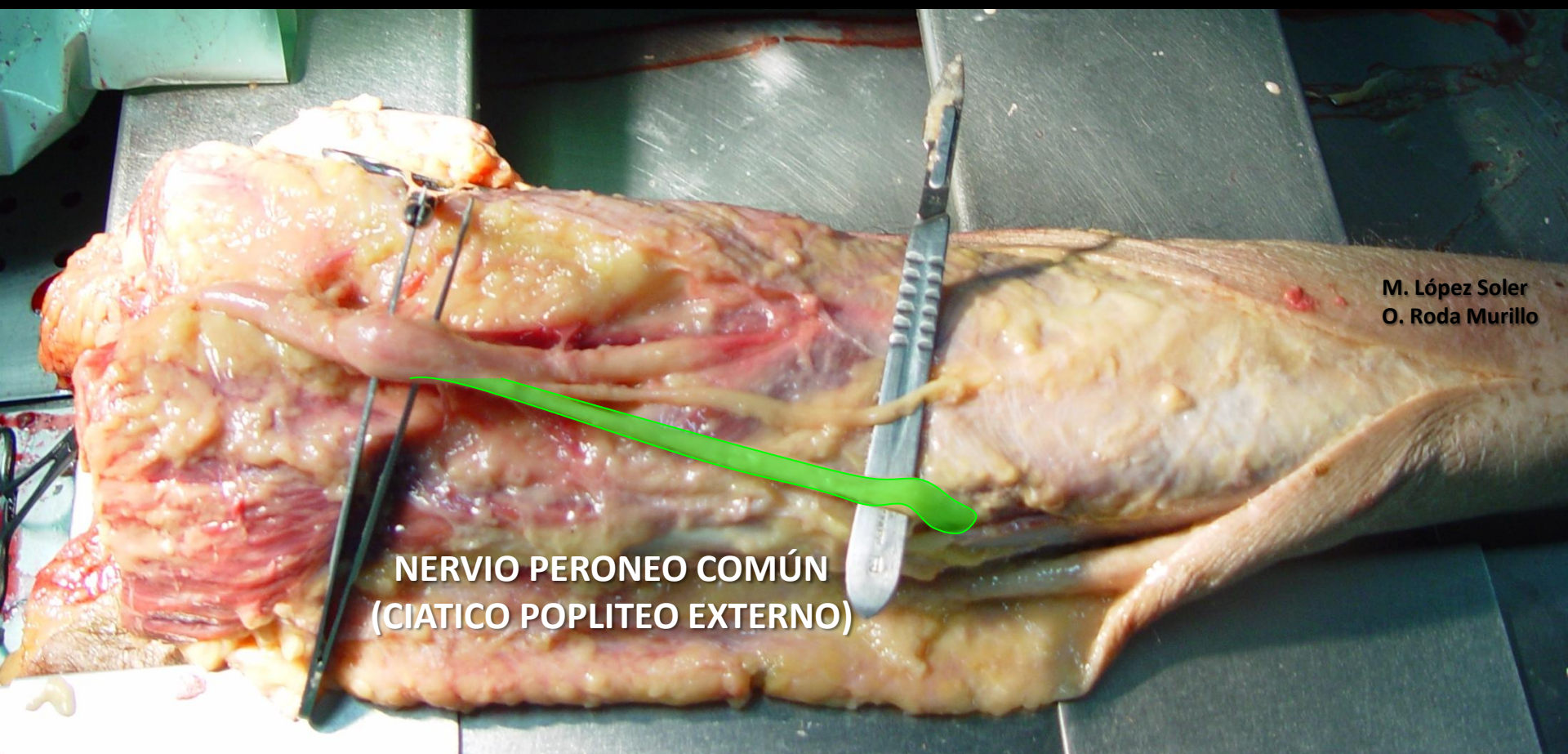M. López Soler
O. Roda Murillo



M. López Soler
O. Roda Murillo

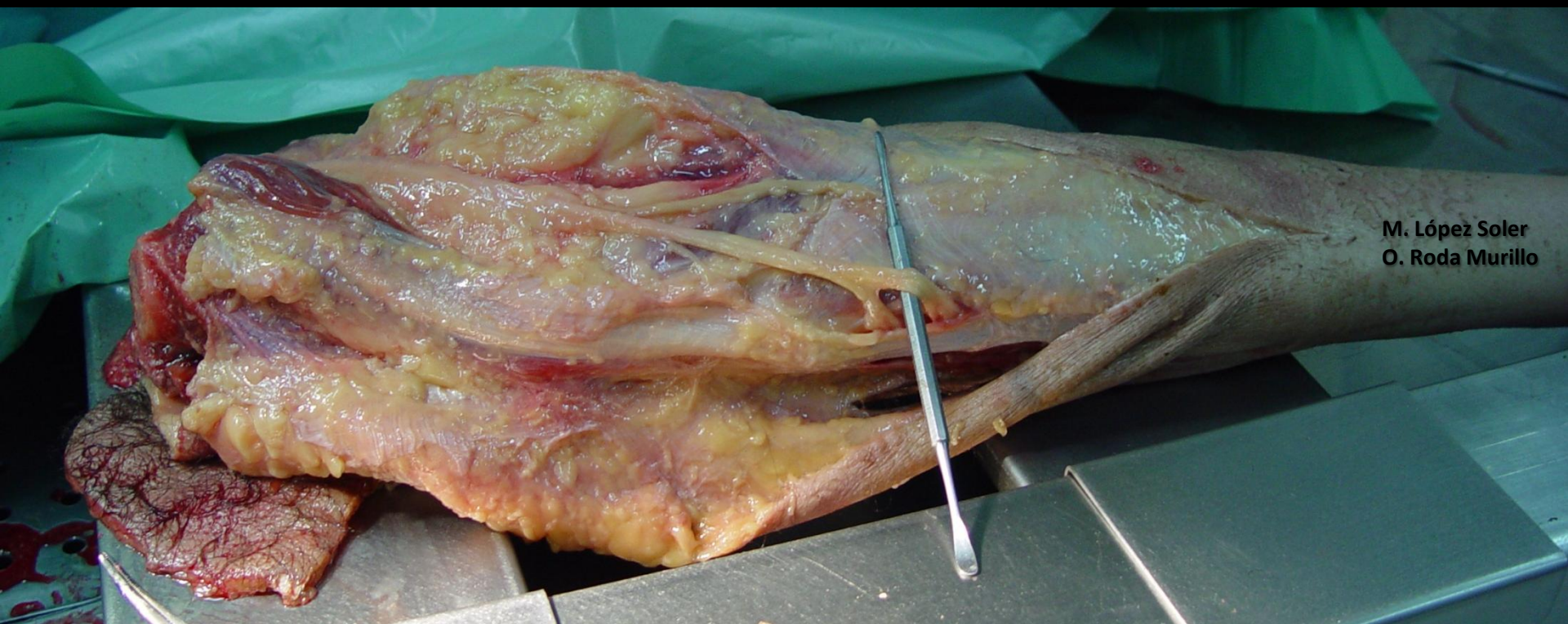


M. López Soler
O. Roda Murillo

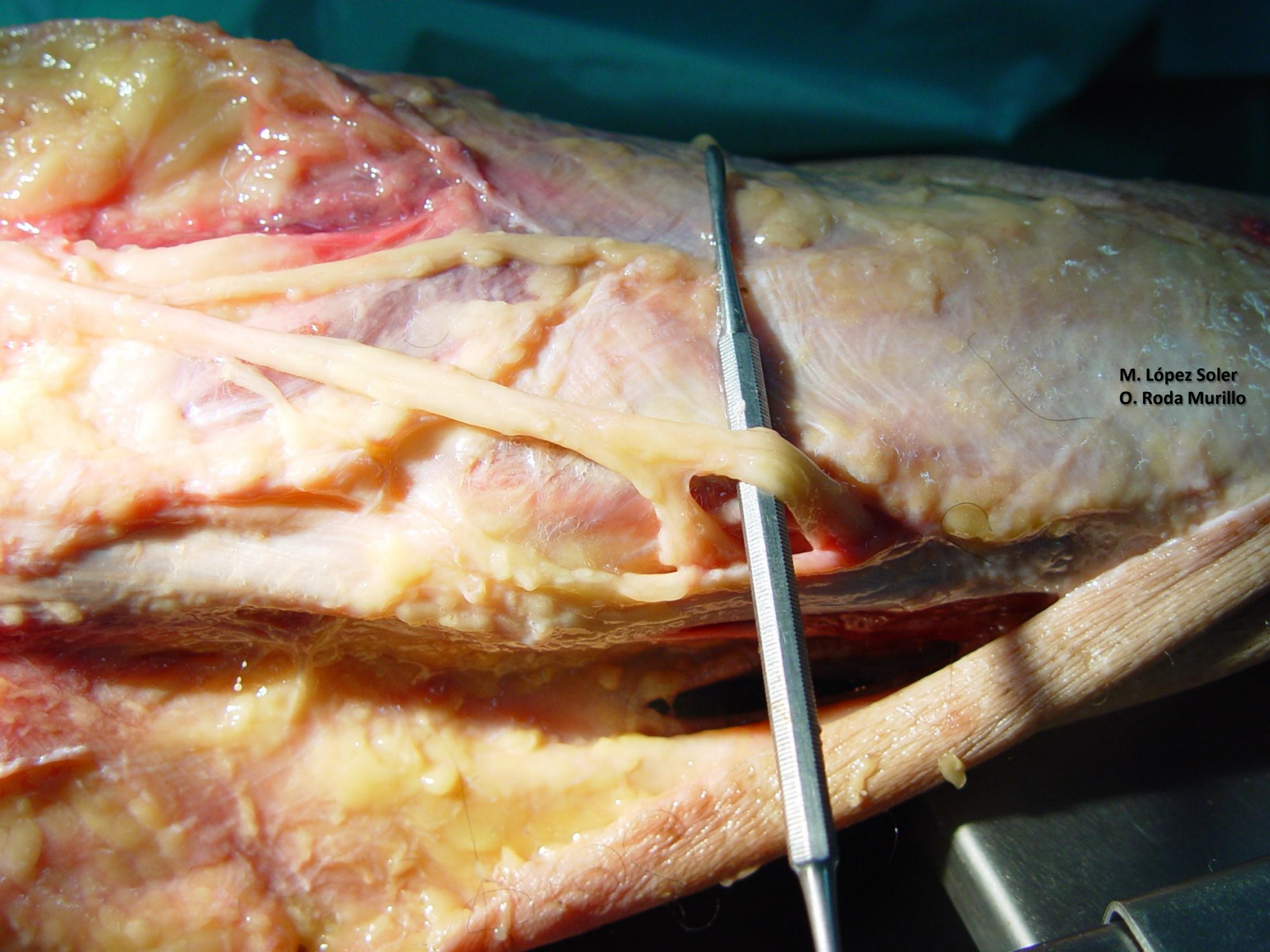


**NERVIO PERONEO COMÚN
(CIÁTICO POPLITEO EXTERNO)**

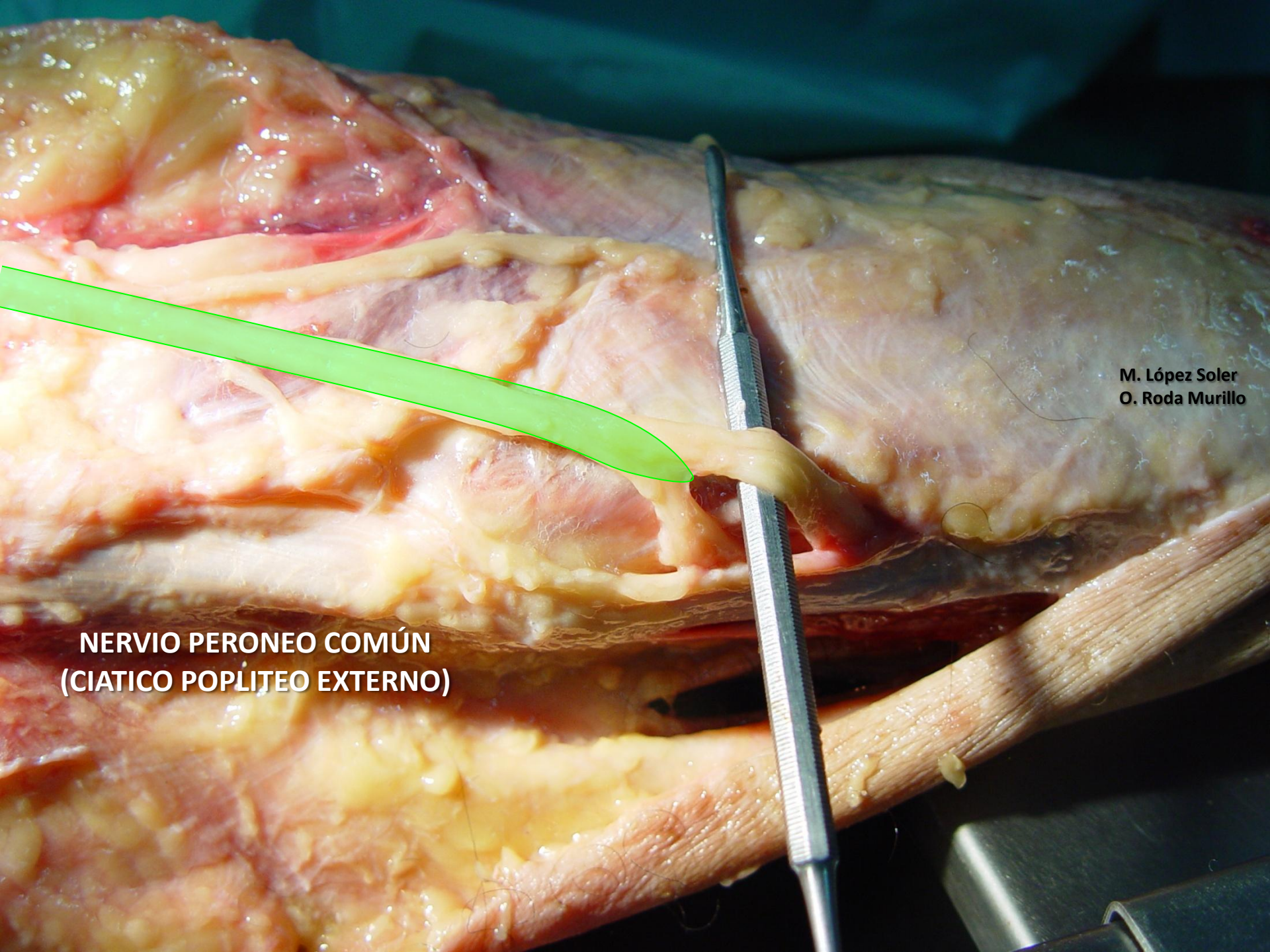
M. López Soler
O. Roda Murillo



M. López Soler
O. Roda Murillo

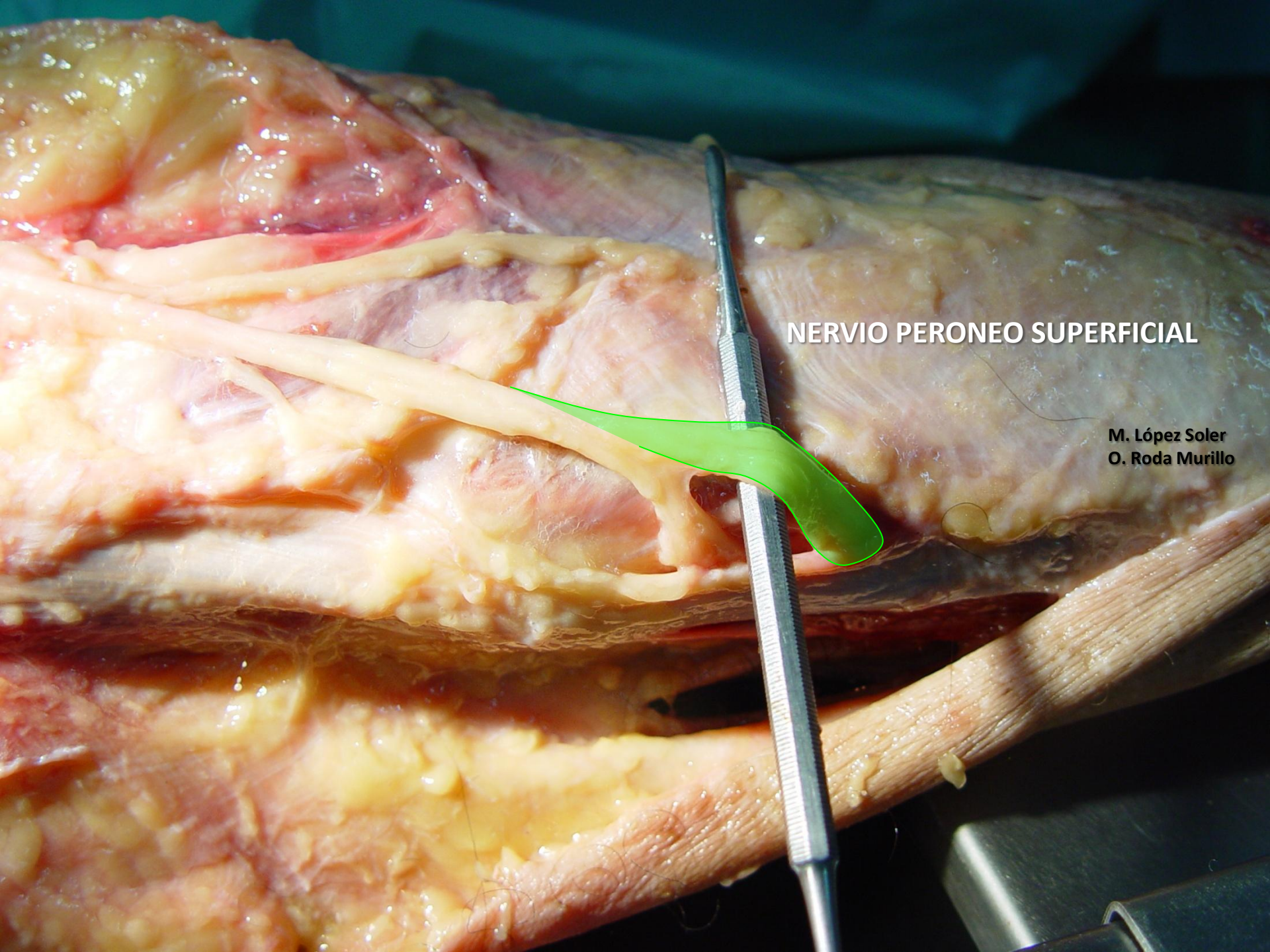


M. López Soler
O. Roda Murillo



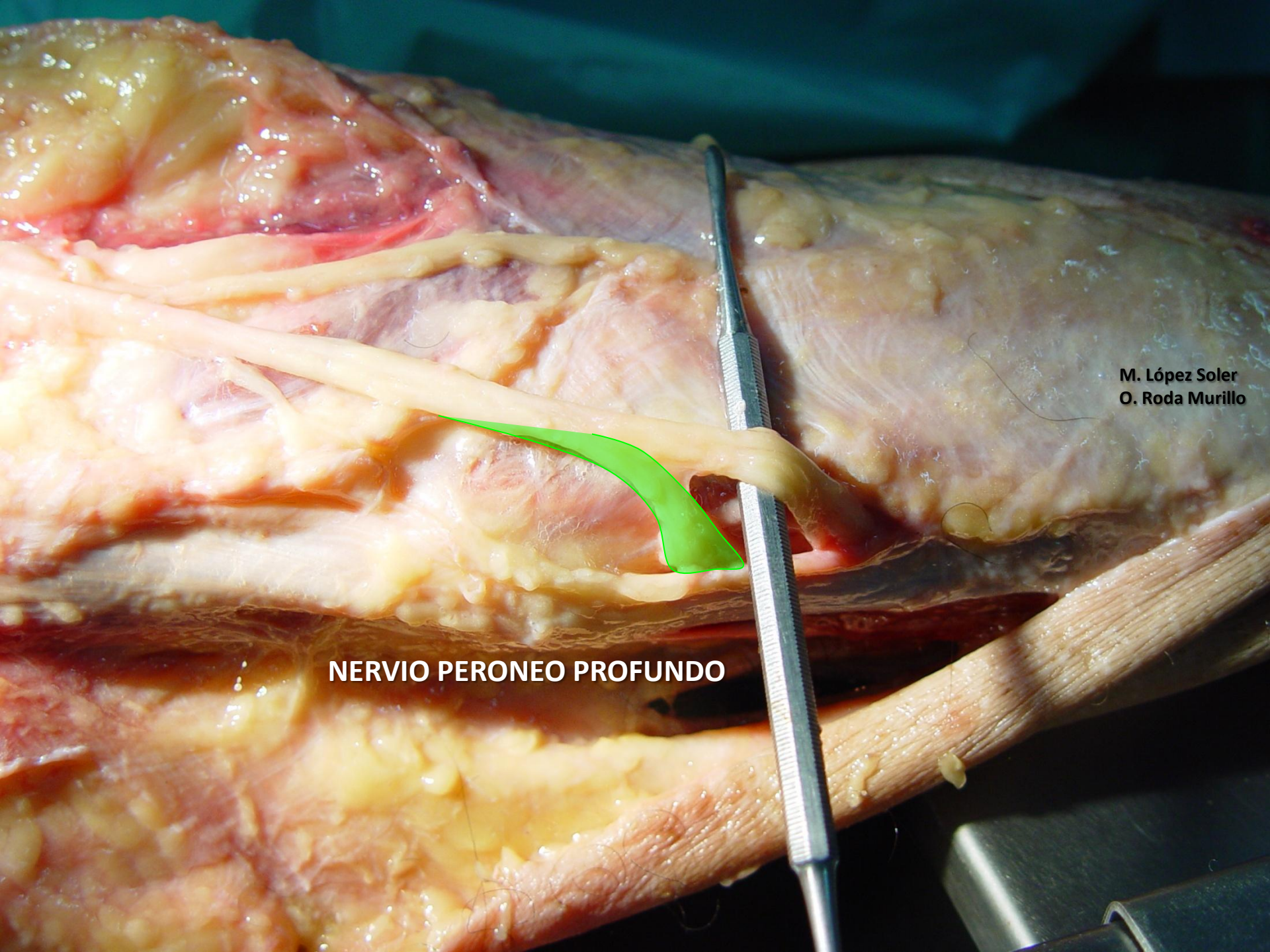
M. López Soler
O. Roda Murillo

**NERVIO PERONEO COMÚN
(CIATICO POPLITEO EXTERNO)**



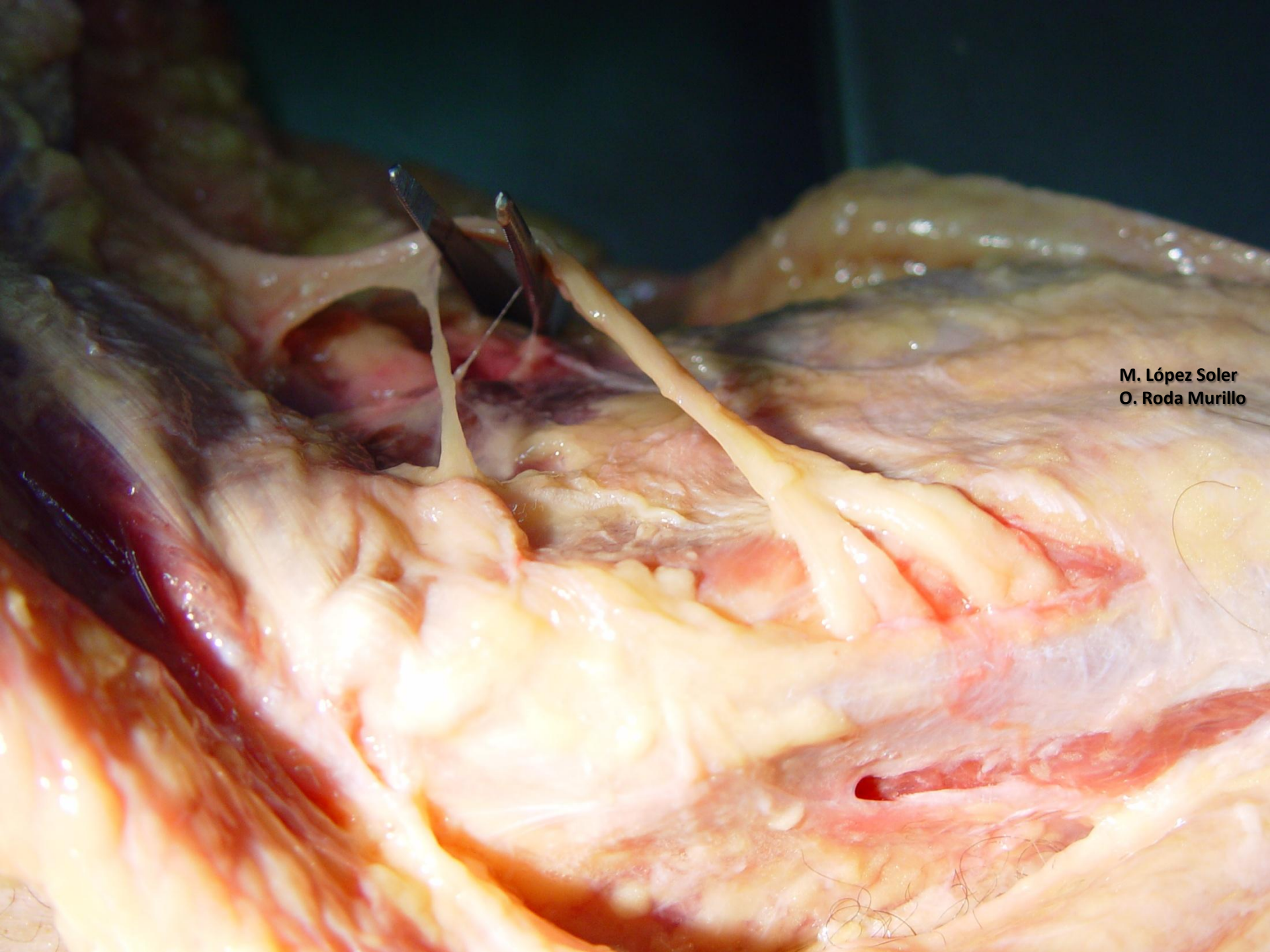
NERVIO PERONEO SUPERFICIAL

**M. López Soler
O. Roda Murillo**



M. López Soler
O. Roda Murillo

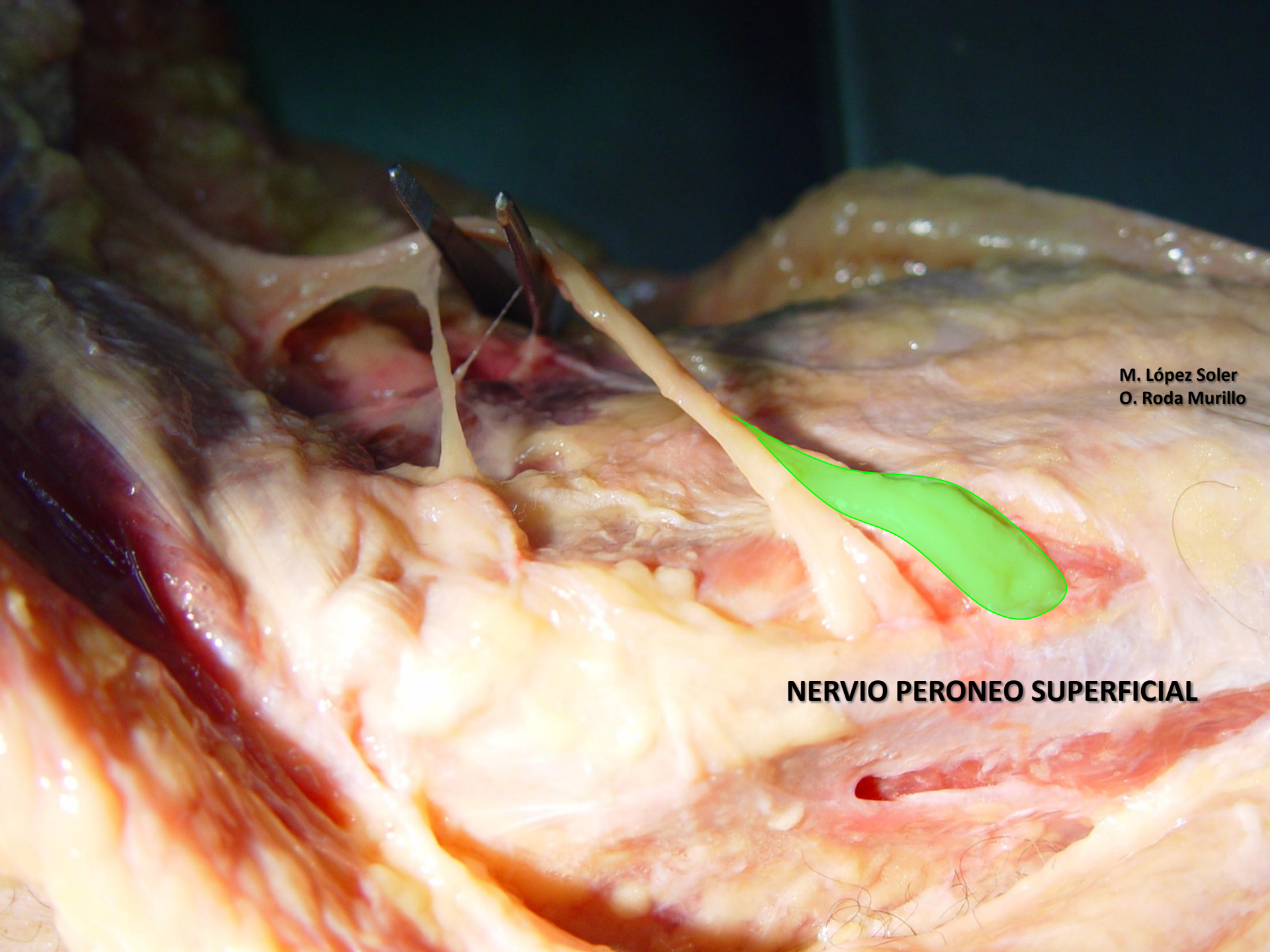
NERVIO PERONEO PROFUNDO



M. López Soler
O. Roda Murillo

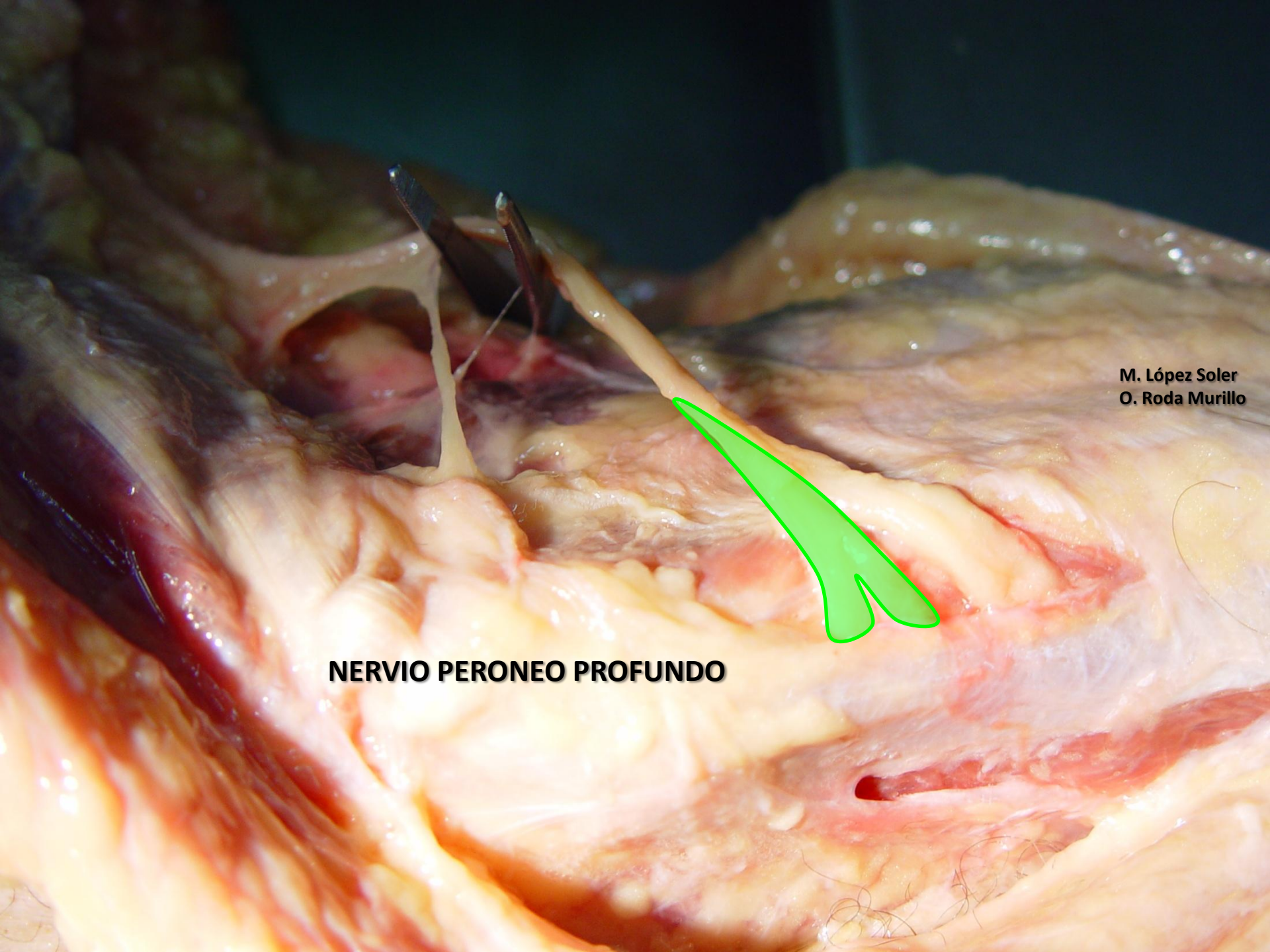
M. López Soler
O. Roda Murillo

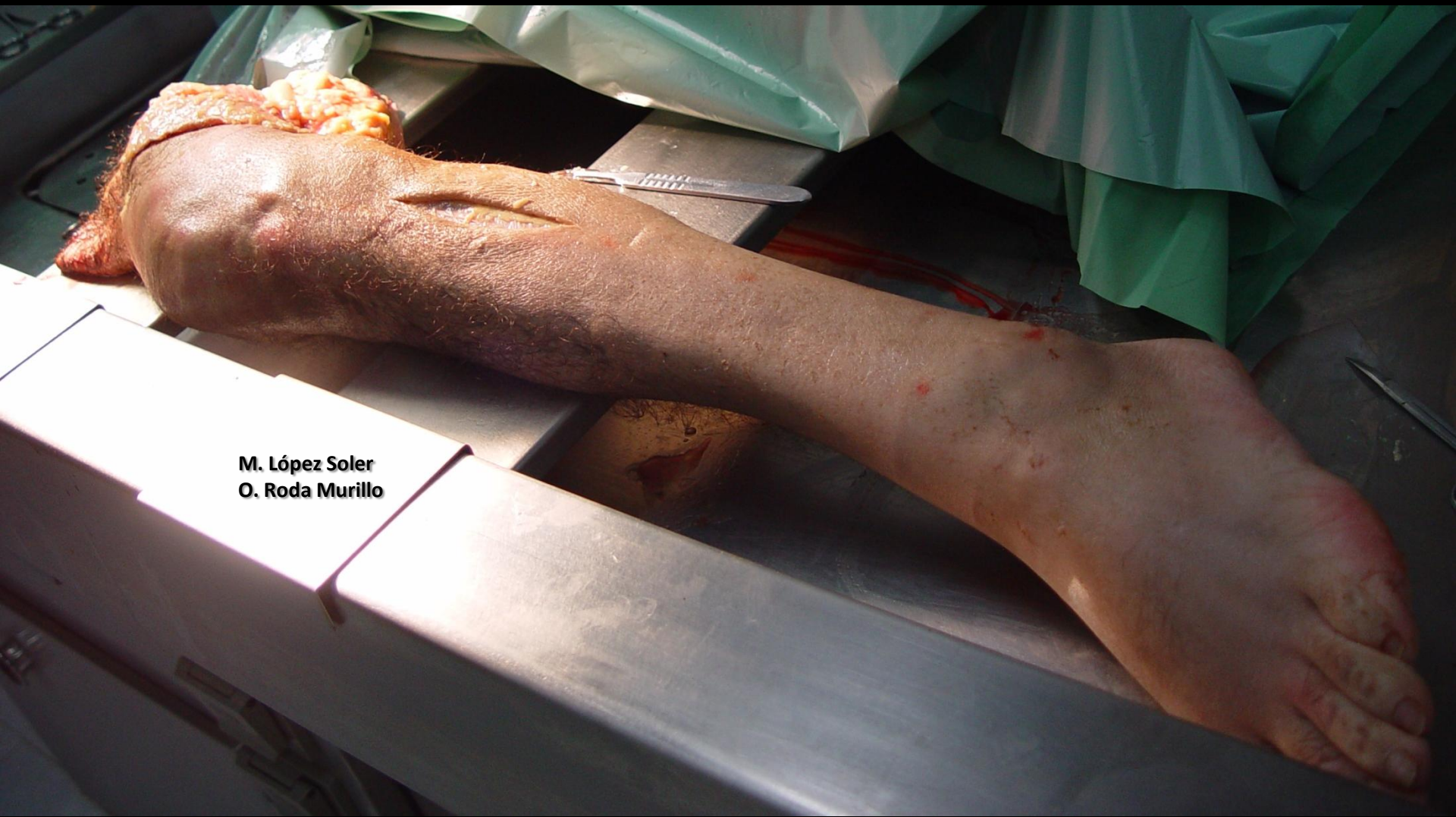NERVIO PERONEO SUPERFICIAL



M. López Soler
O. Roda Murillo

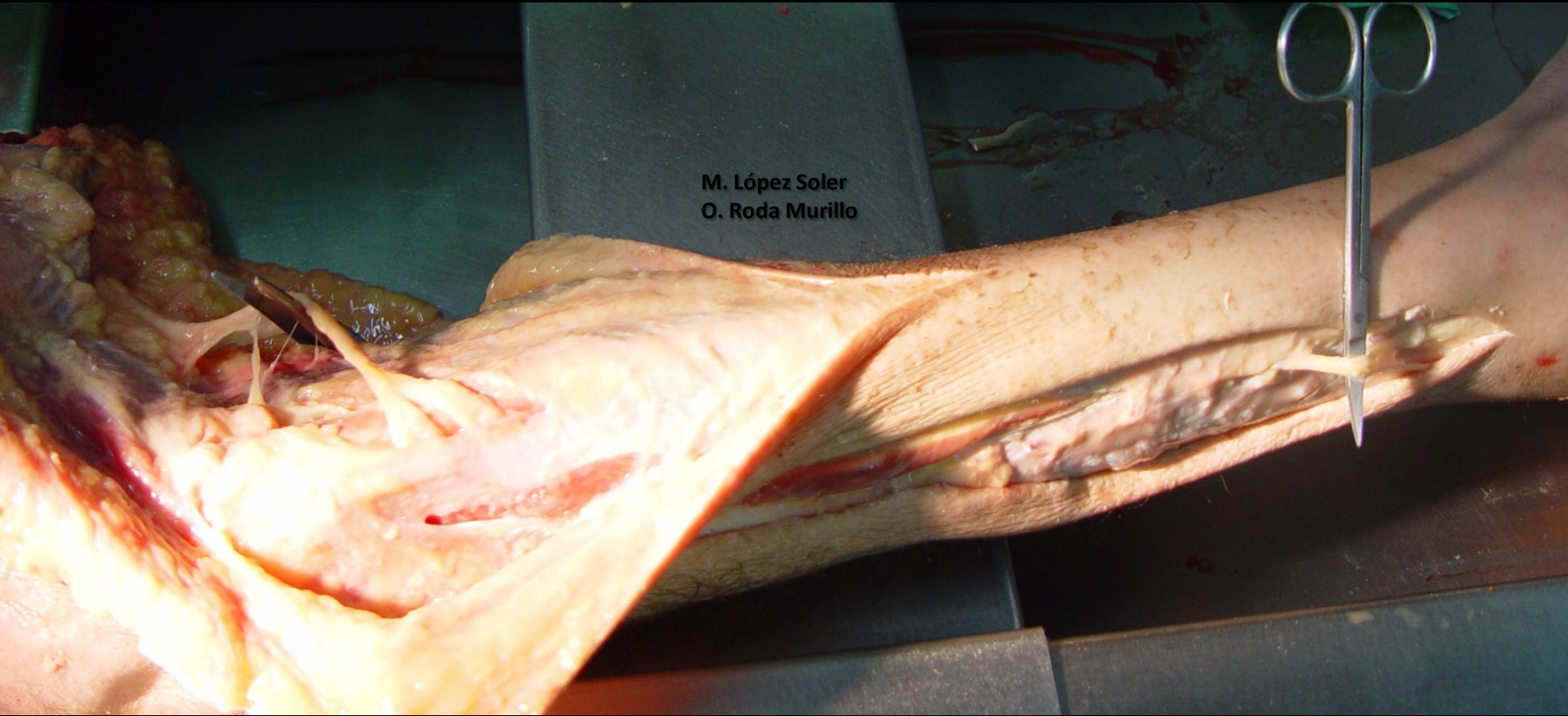
NERVIO PERONEO PROFUNDO





M. López Soler
O. Roda Murillo

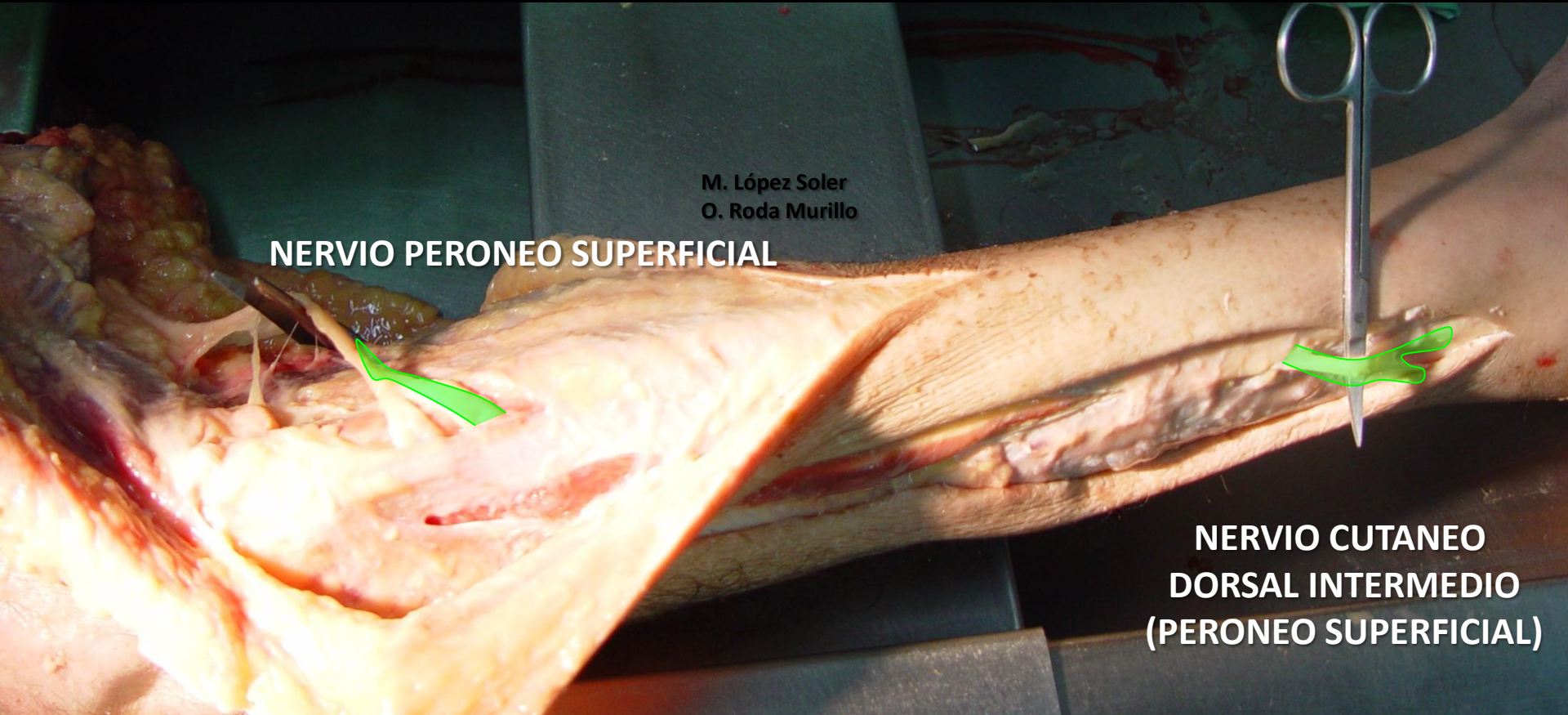M. López Soler
O. Roda Murillo

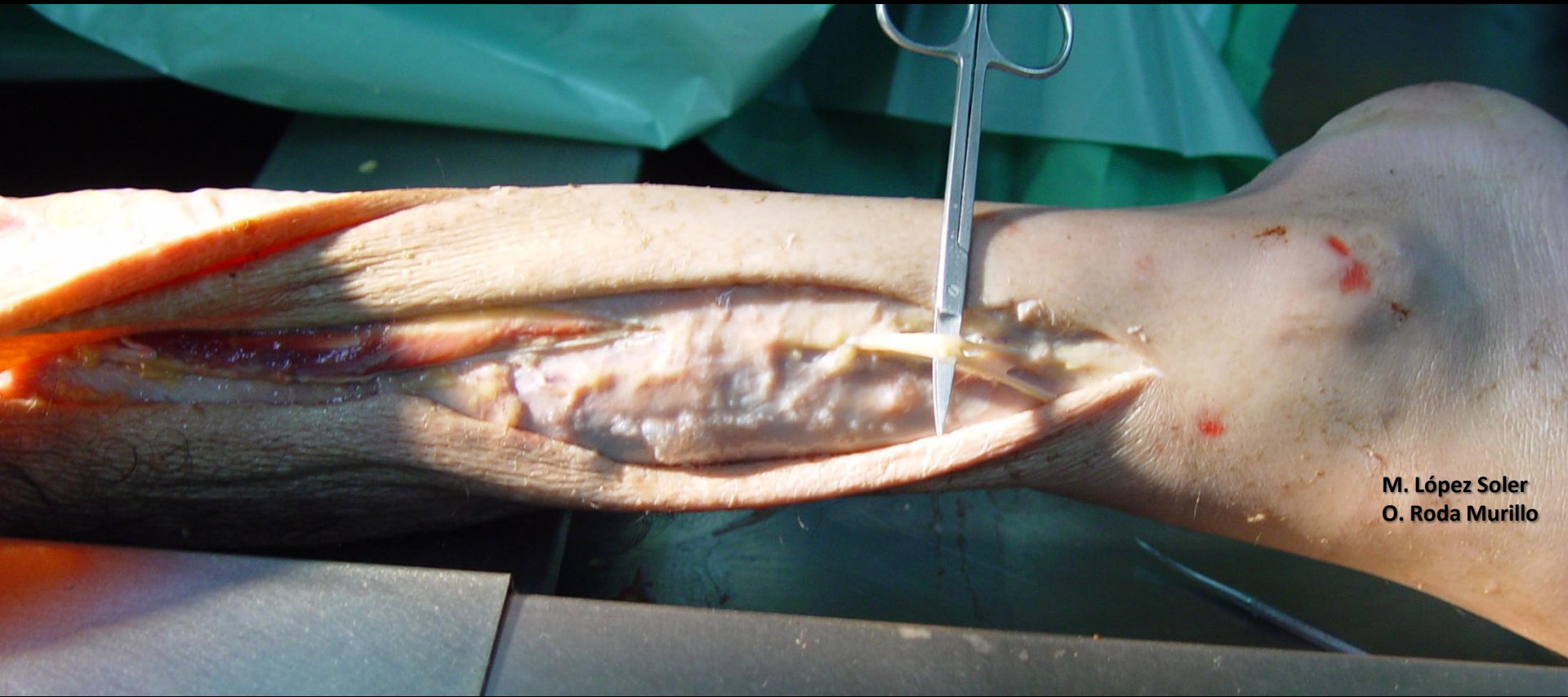

M. López Soler
O. Roda Murillo

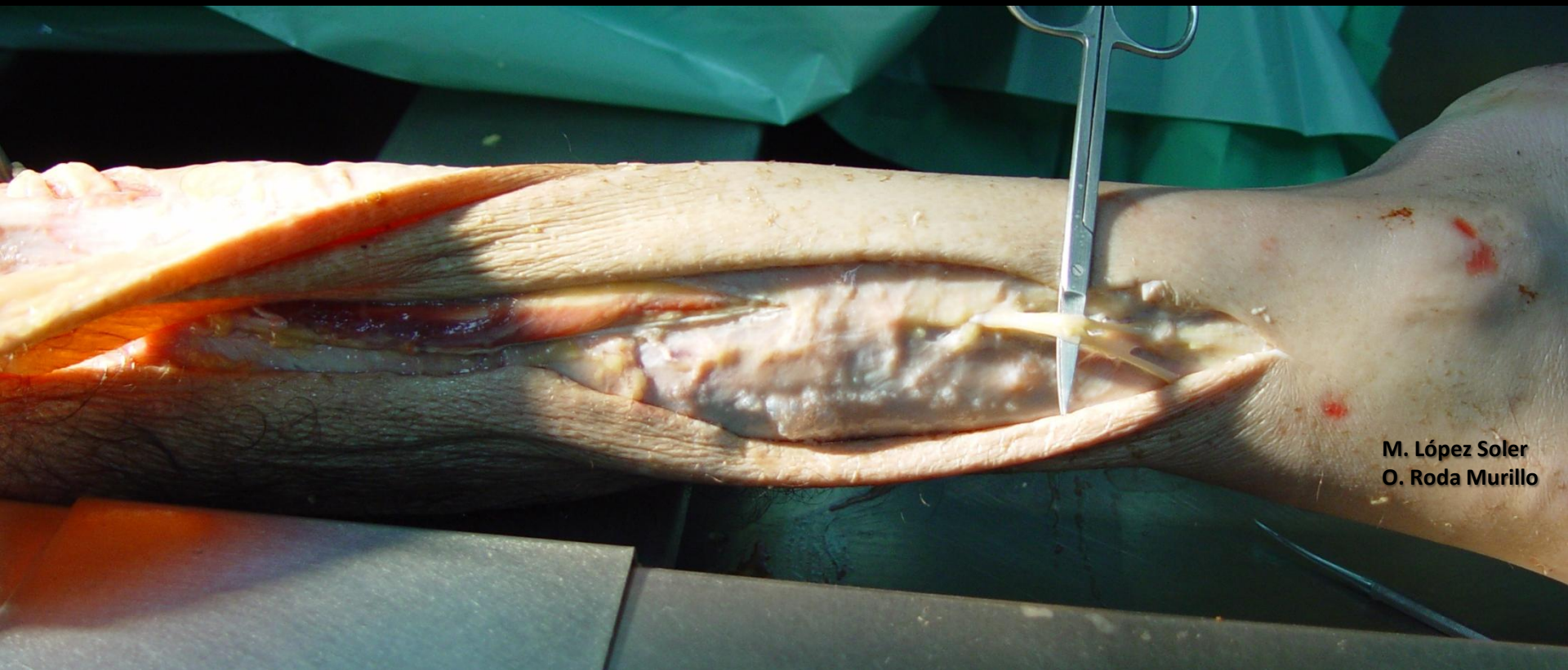
NERVIO PERONEO SUPERFICIAL

**NERVIO CUTANEO
DORSAL INTERMEDIO
(PERONEO SUPERFICIAL)**



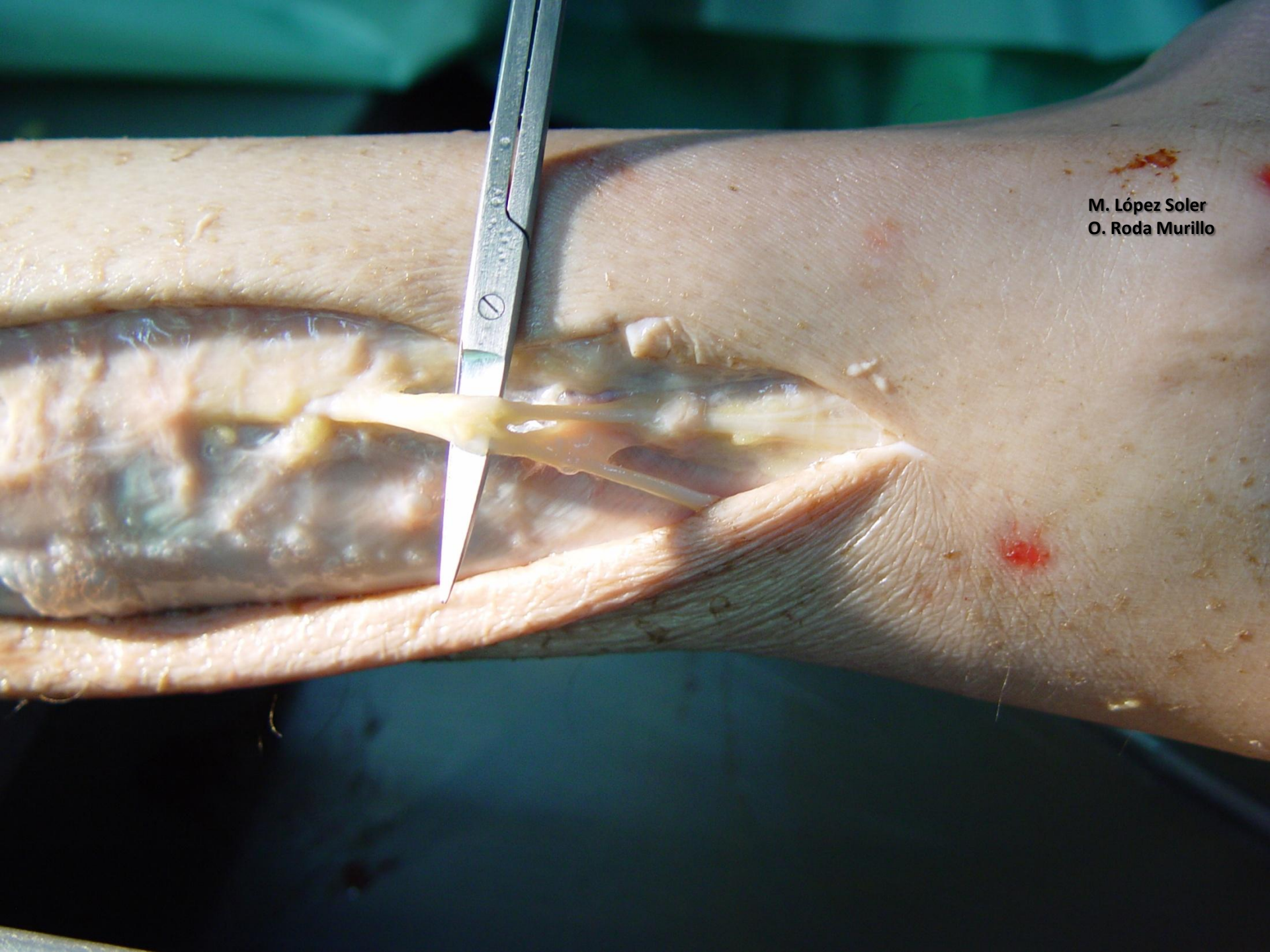


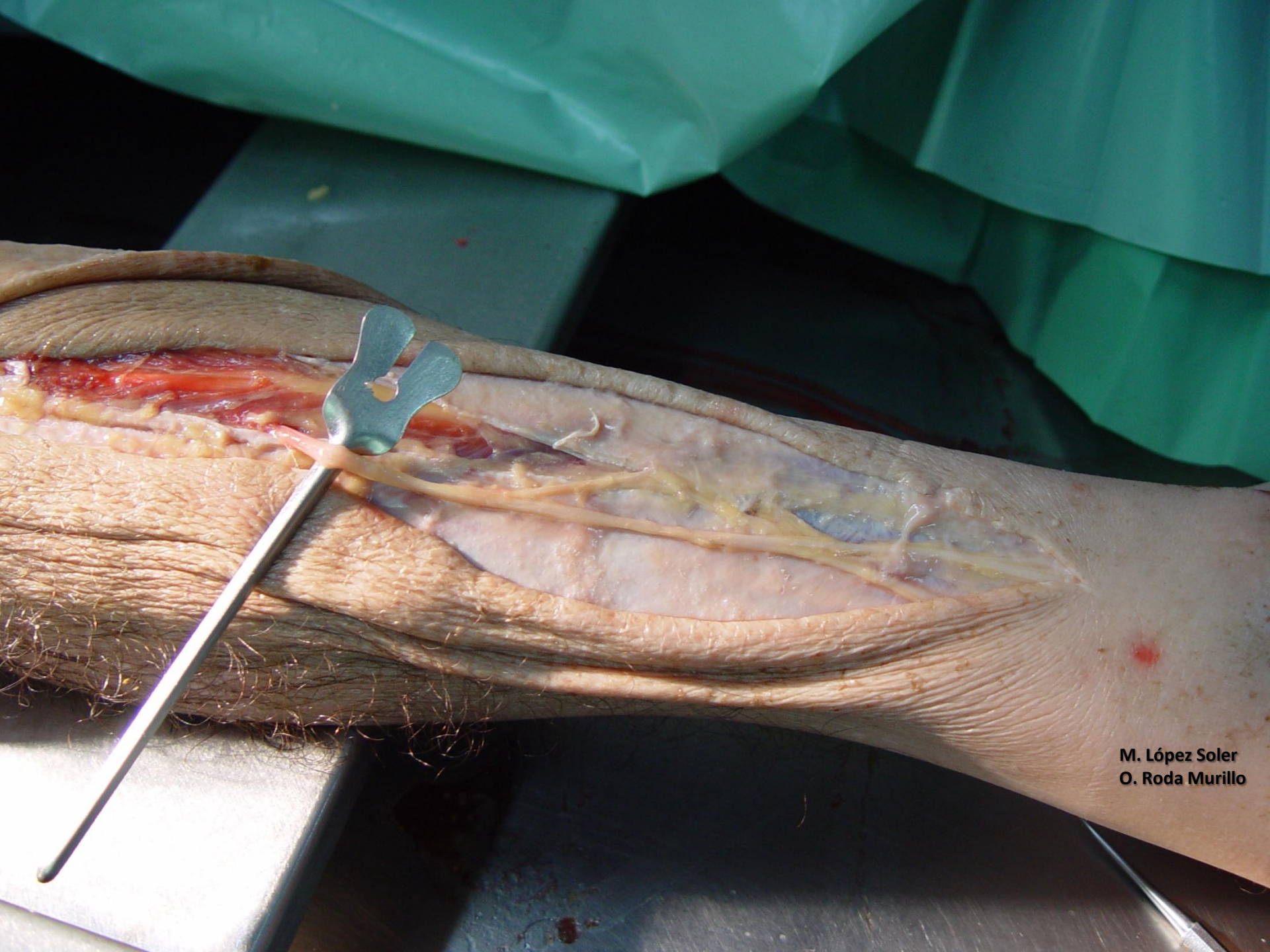
M. López Soler
O. Roda Murillo



M. López Soler
O. Roda Murillo

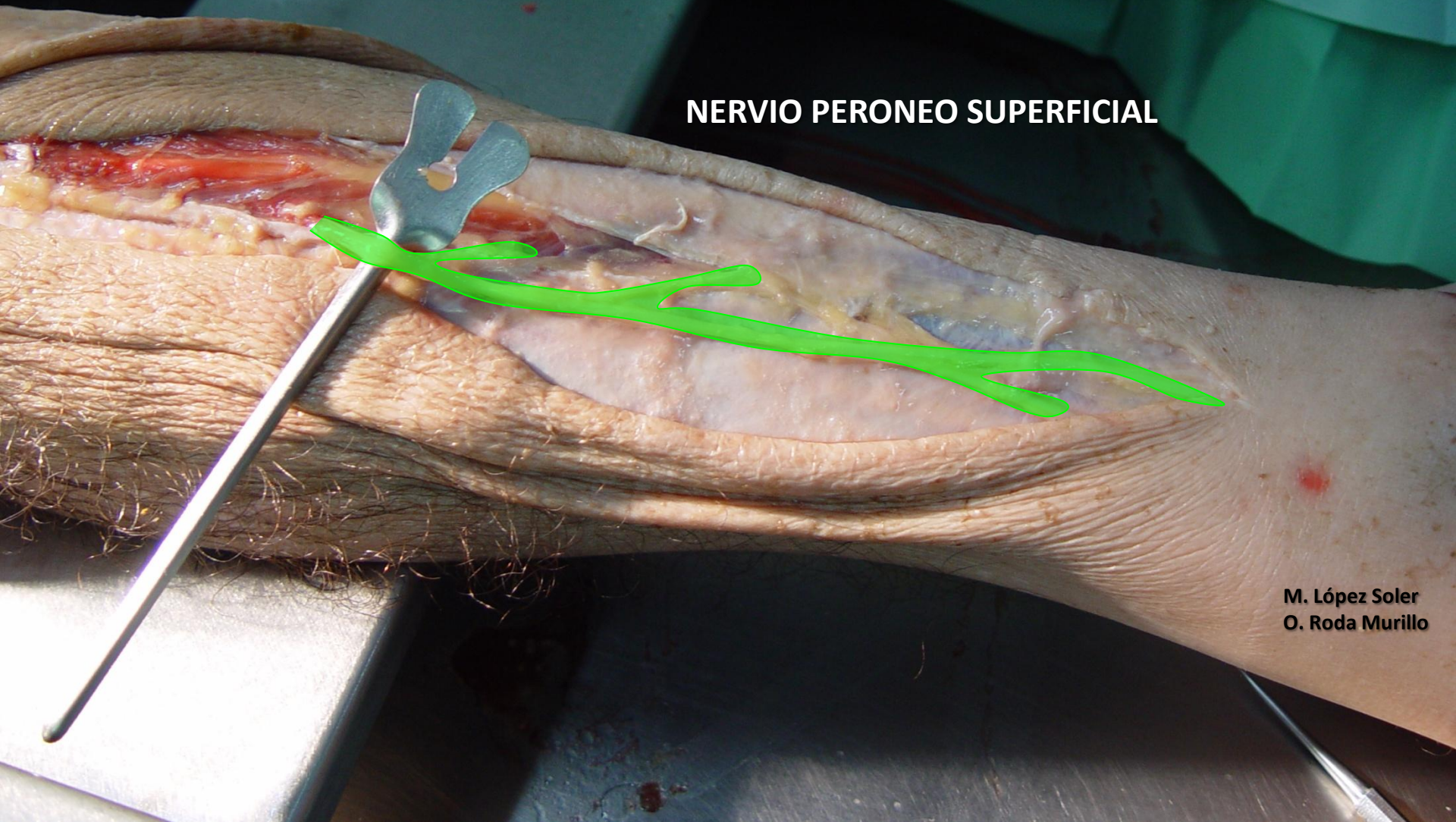M. López Soler
O. Roda Murillo



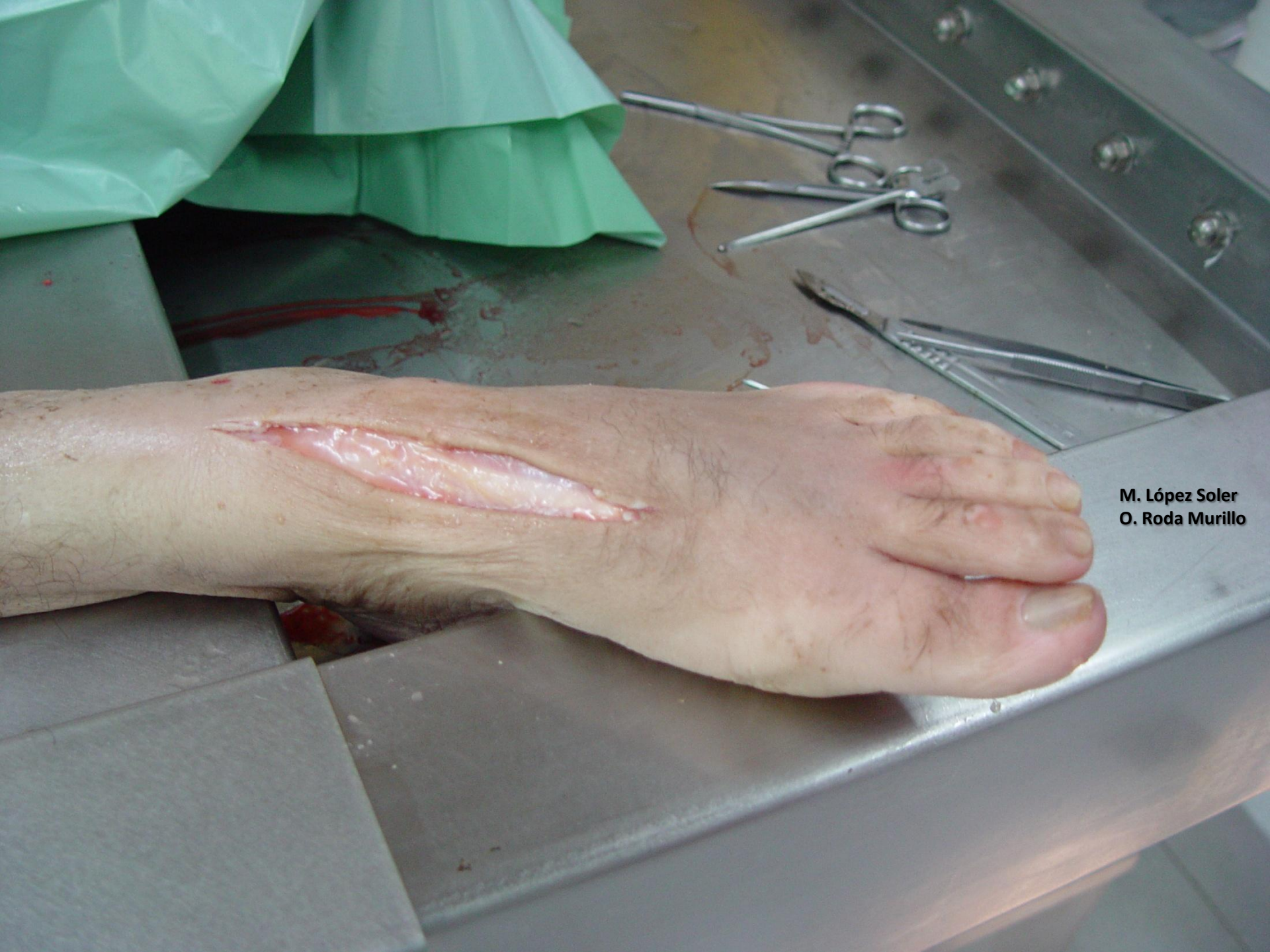

M. López Soler
O. Roda Murillo

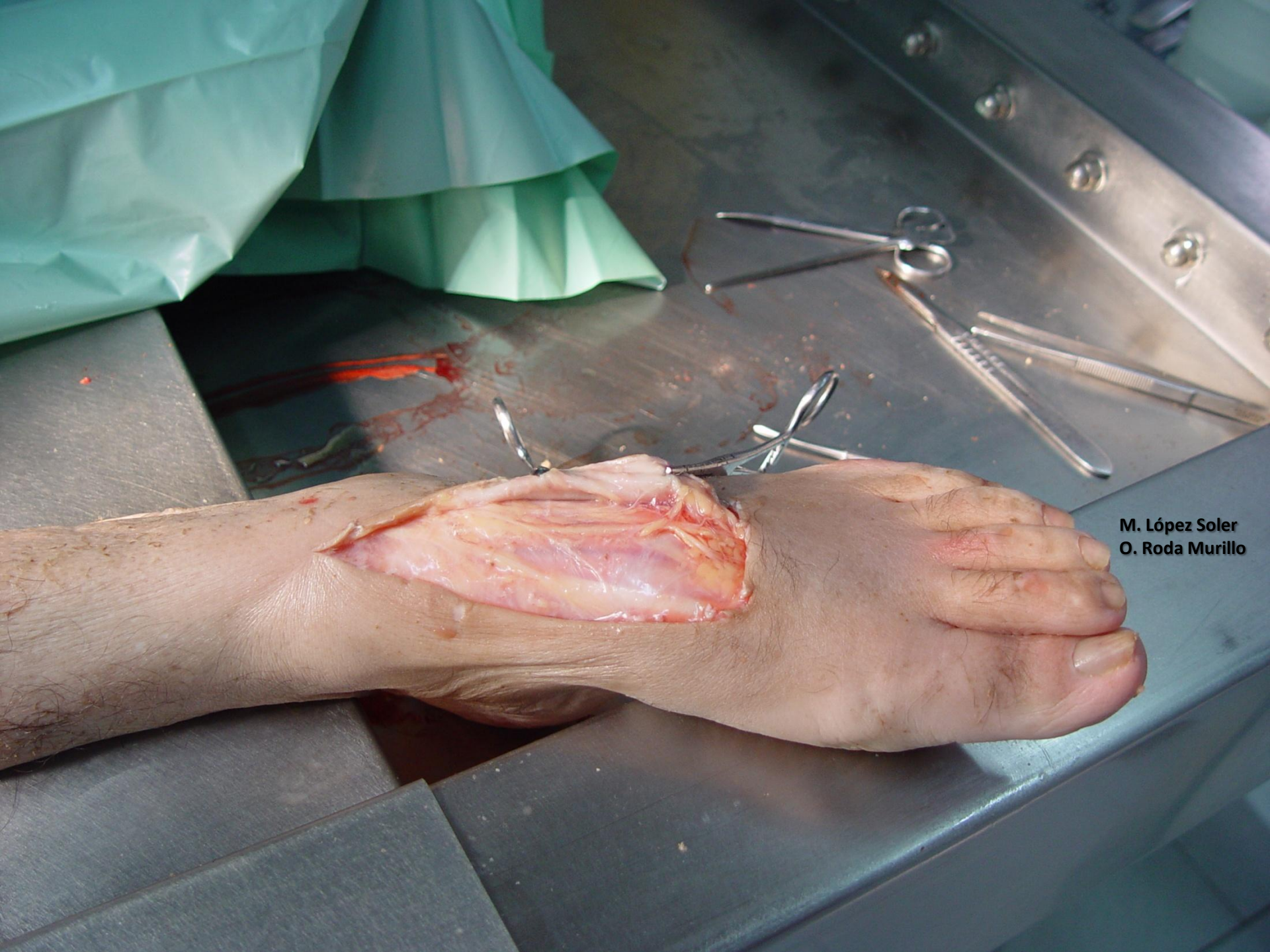NERVIO PERONEO SUPERFICIAL



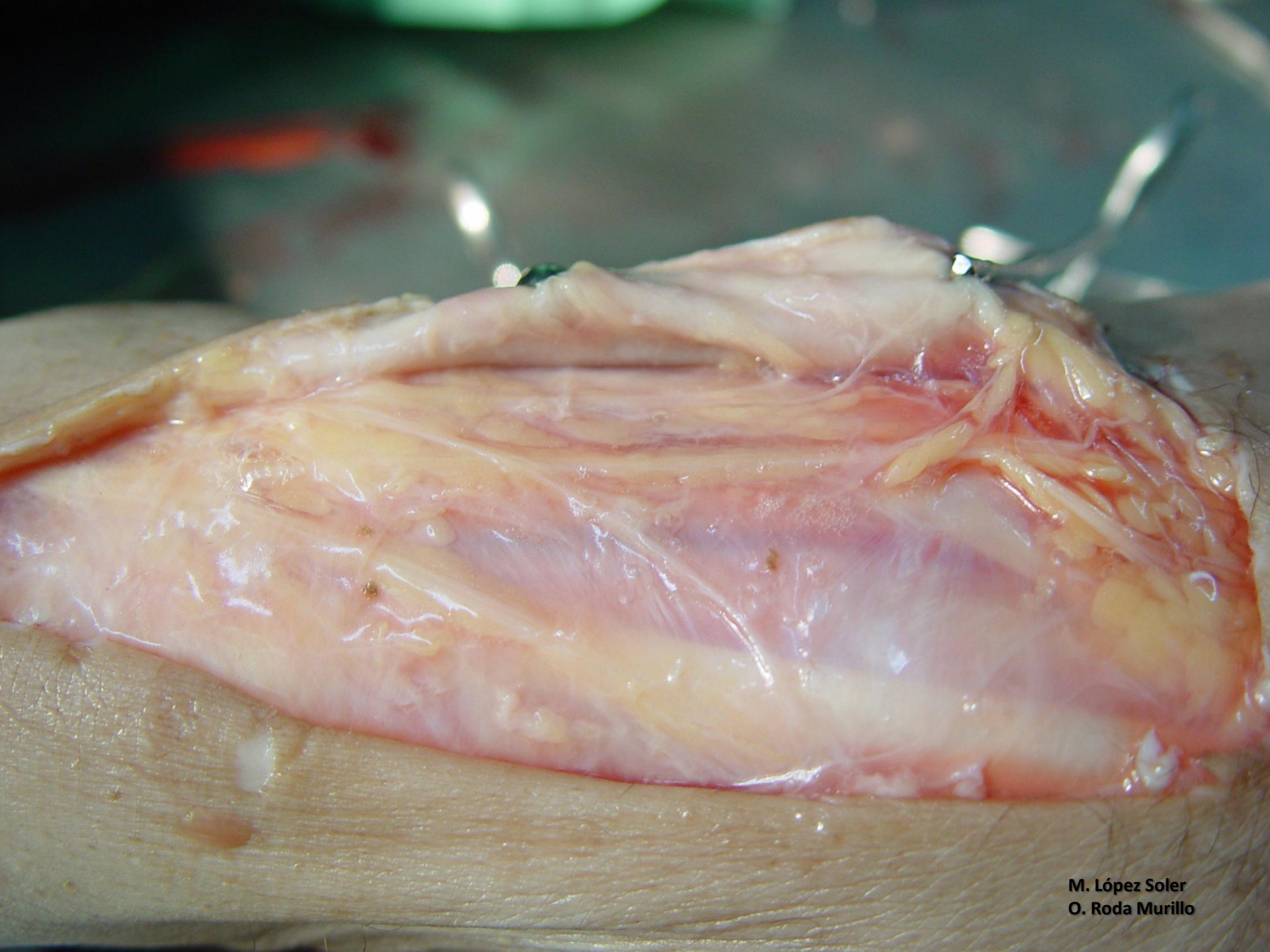
**M. López Soler
O. Roda Murillo**



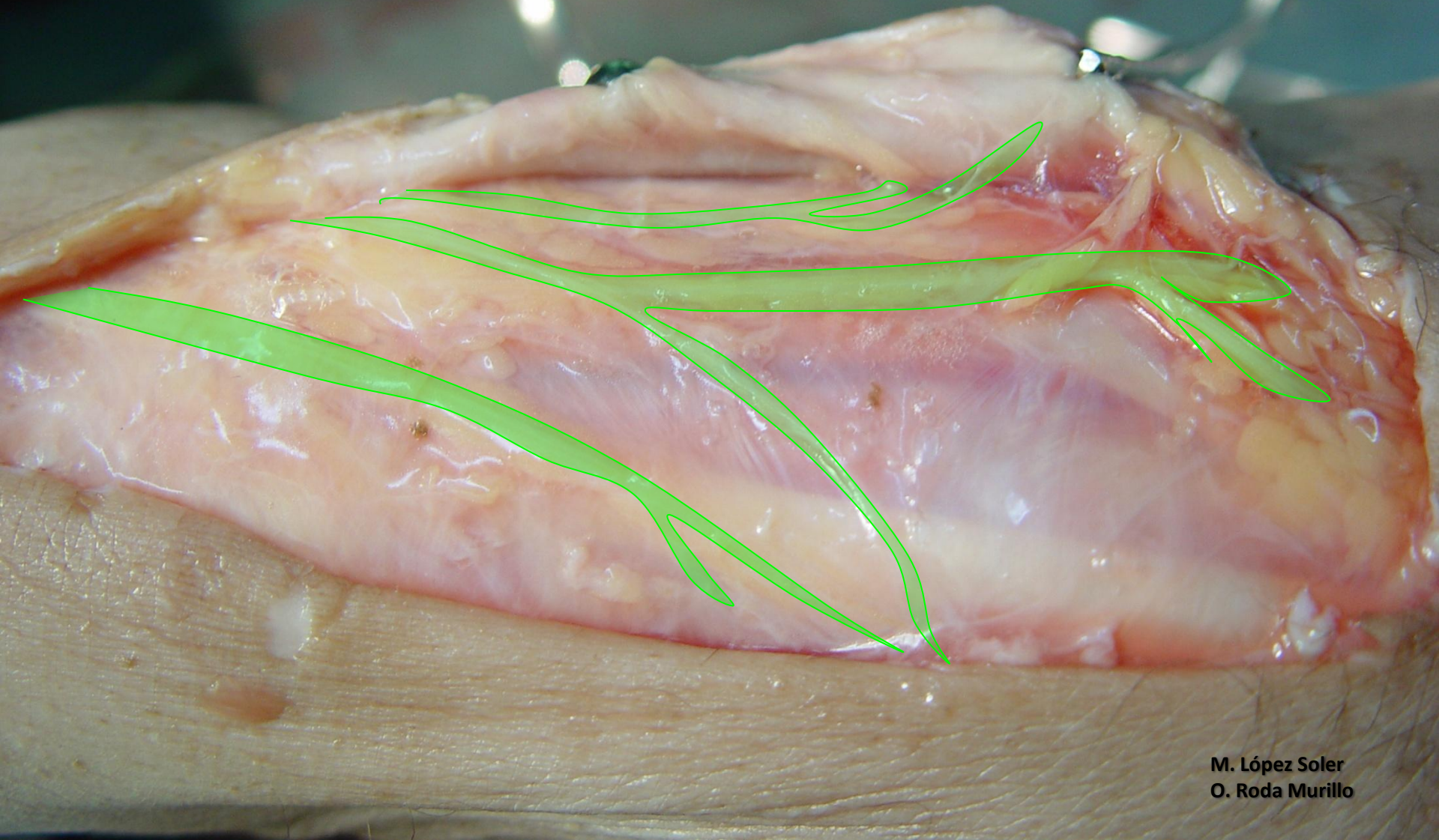M. López Soler
O. Roda Murillo

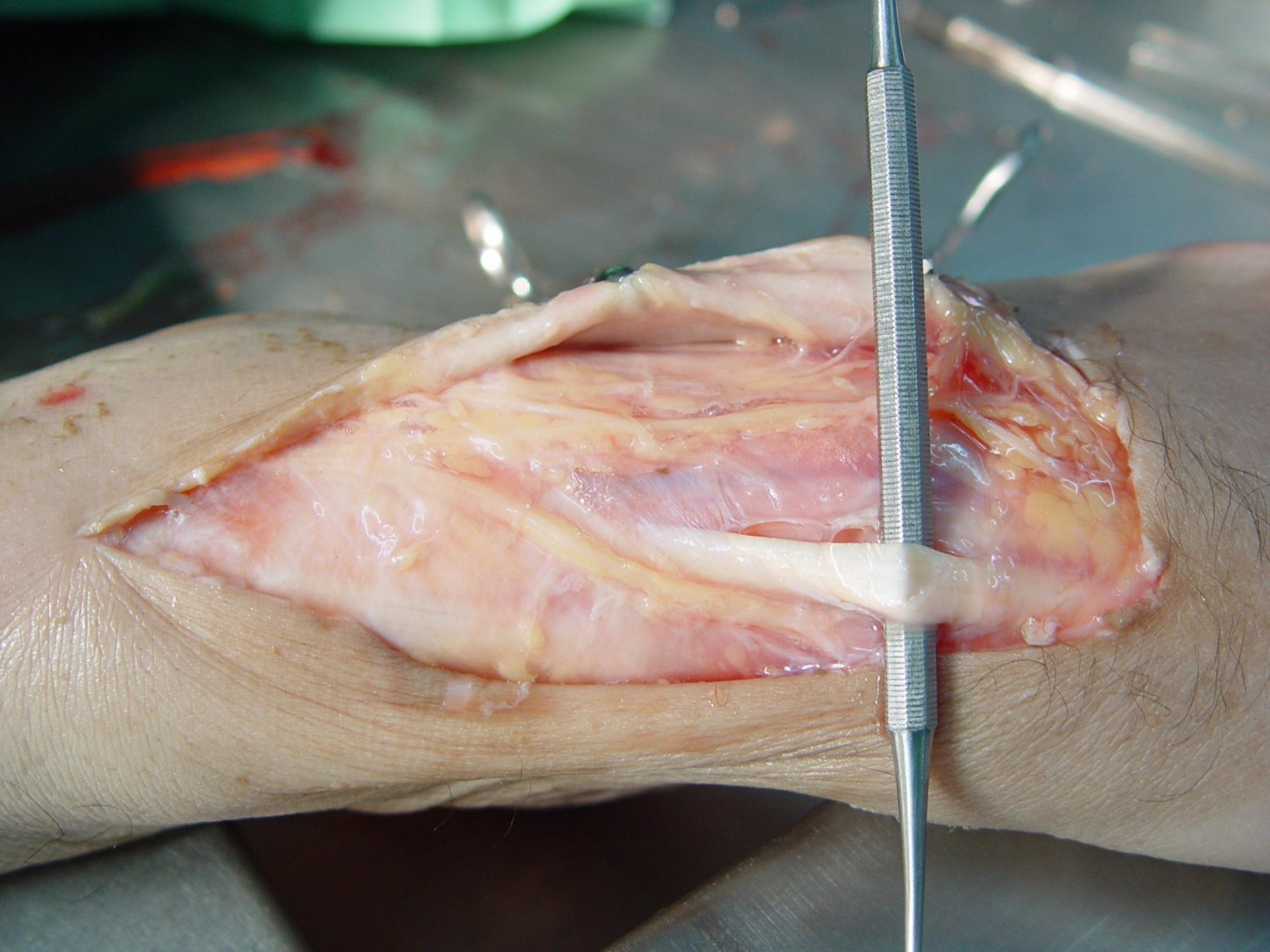


M. López Soler
O. Roda Murillo

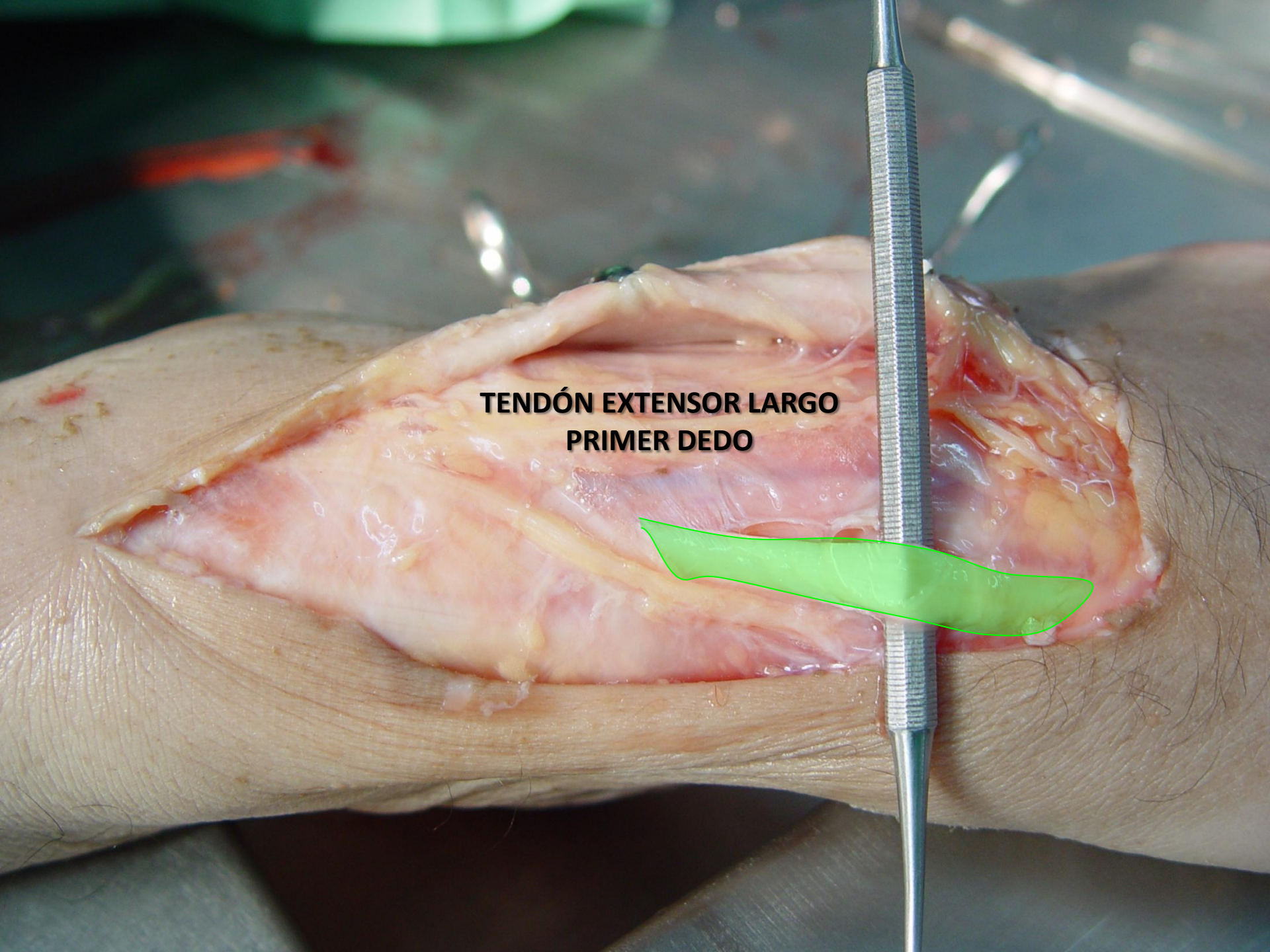
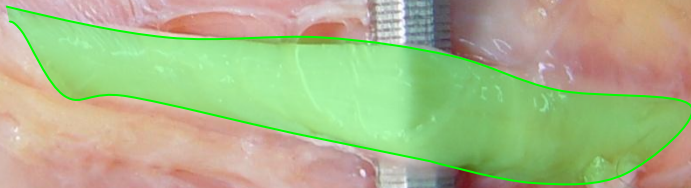


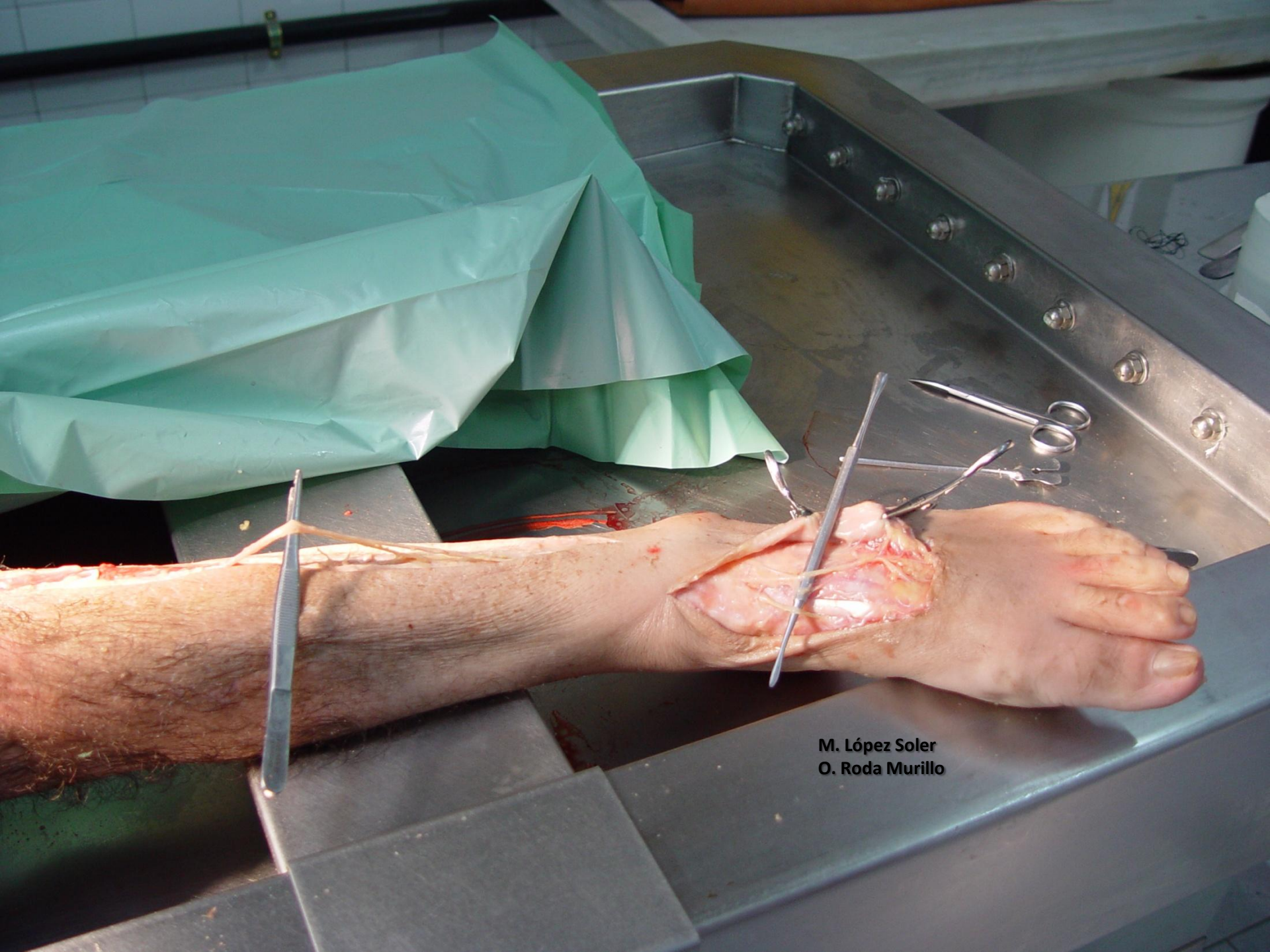
**NERVIOS DIGITALES
(PERONEO SUPERFICIAL)**



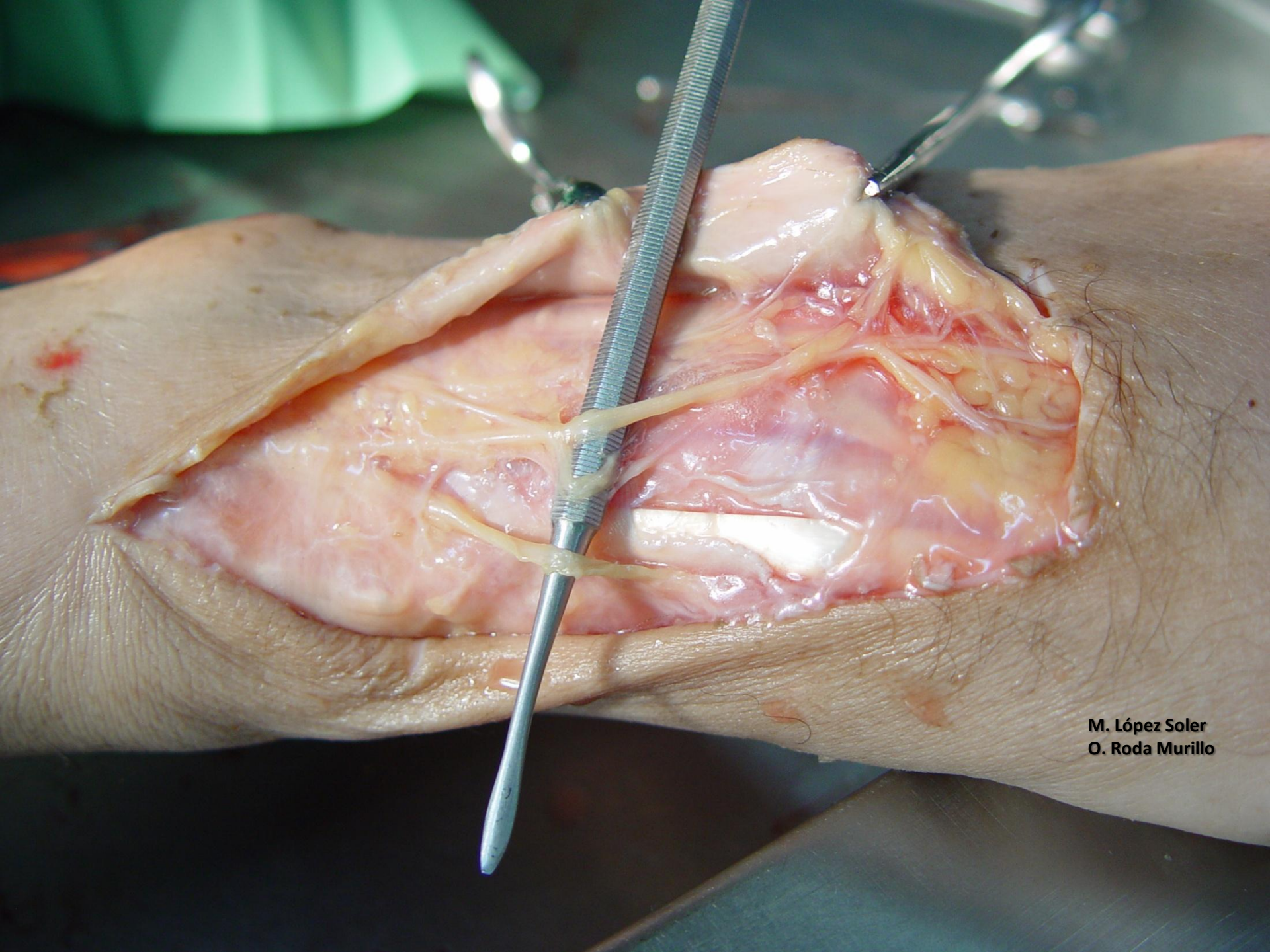


**TENDÓN EXTENSOR LARGO
PRIMER DEDO**

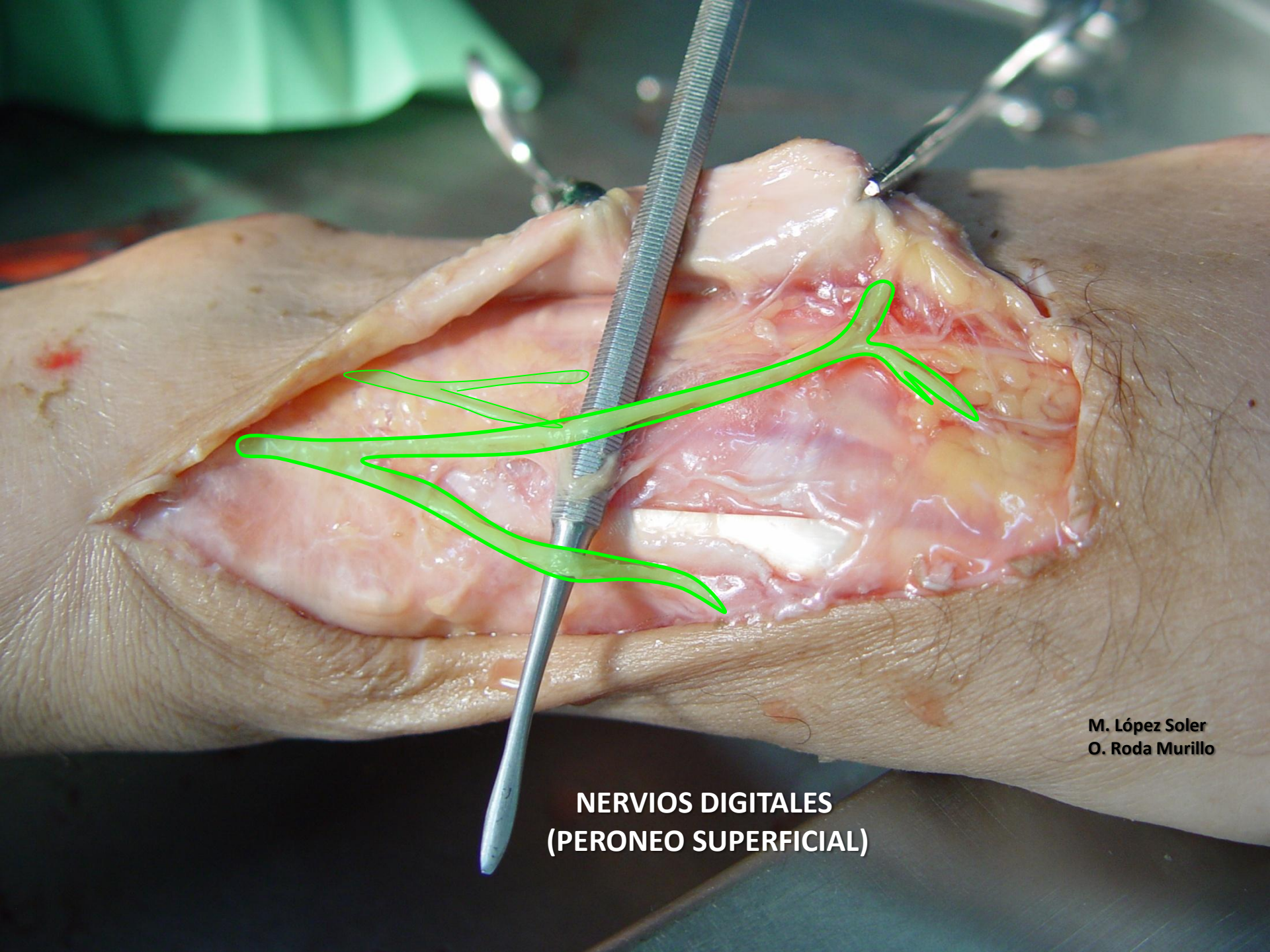




M. López Soler
O. Roda Murillo

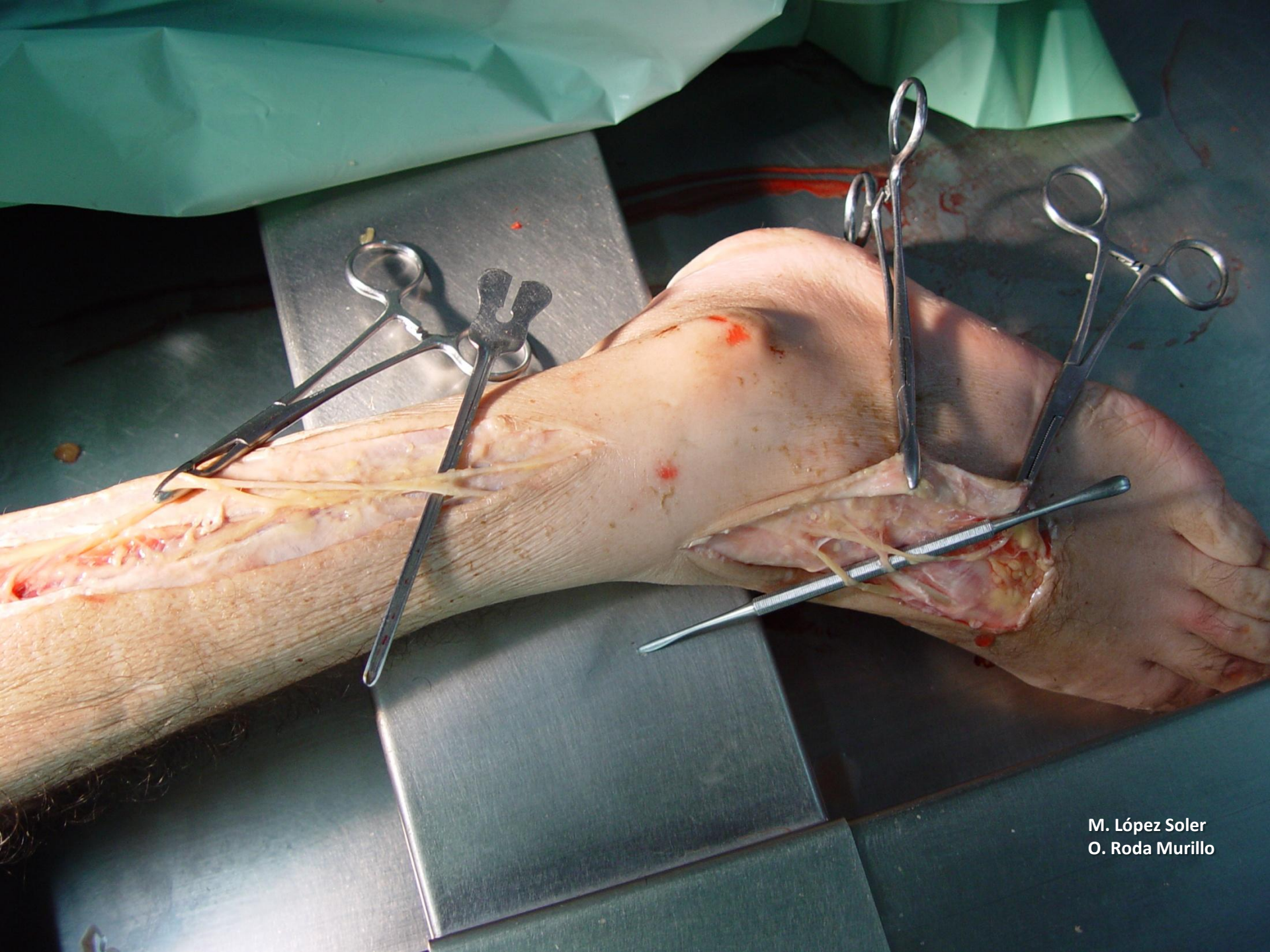


M. López Soler
O. Roda Murillo

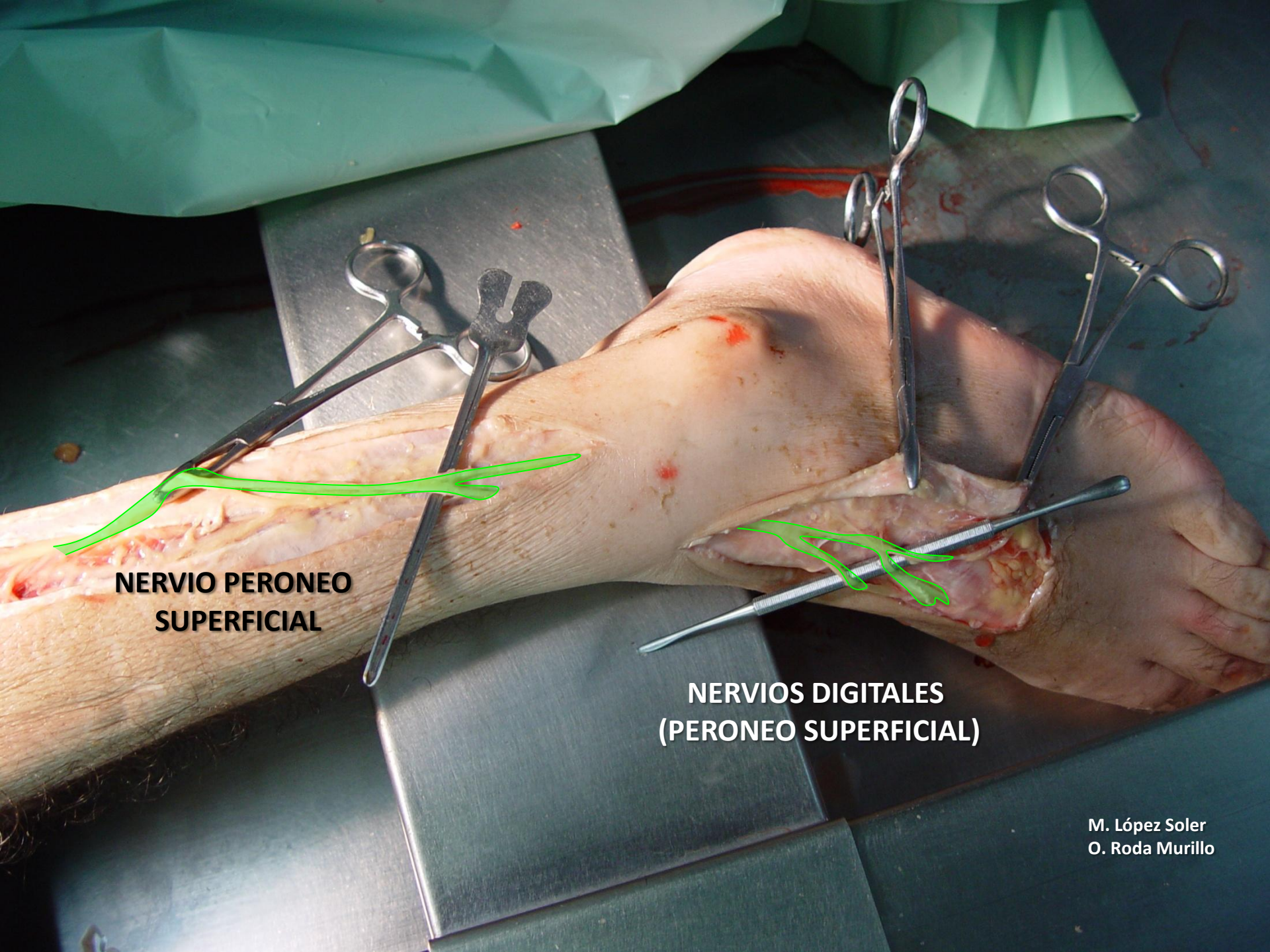


M. López Soler
O. Roda Murillo

**NERVIOS DIGITALES
(PERONEO SUPERFICIAL)**



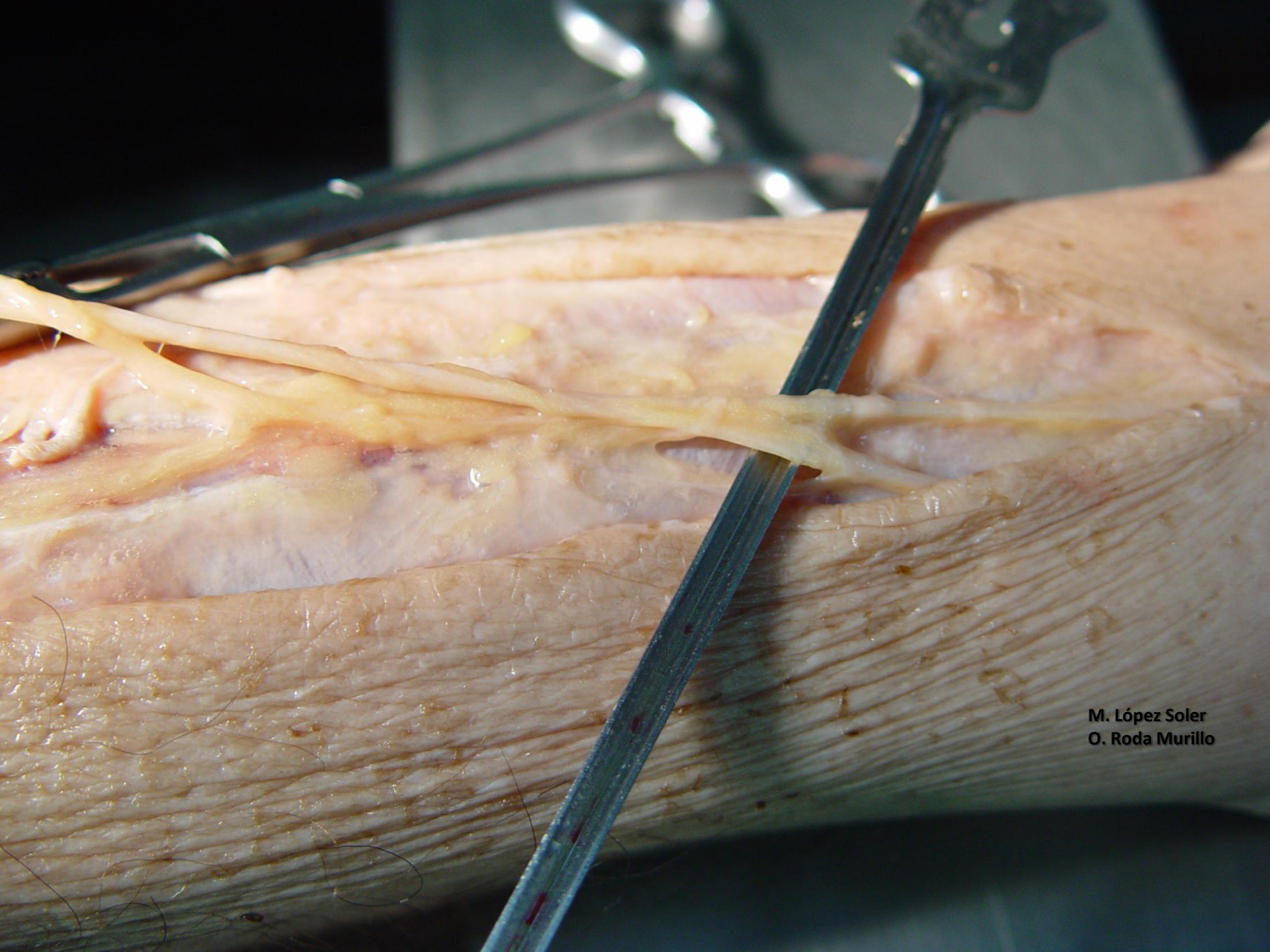
M. López Soler
O. Roda Murillo



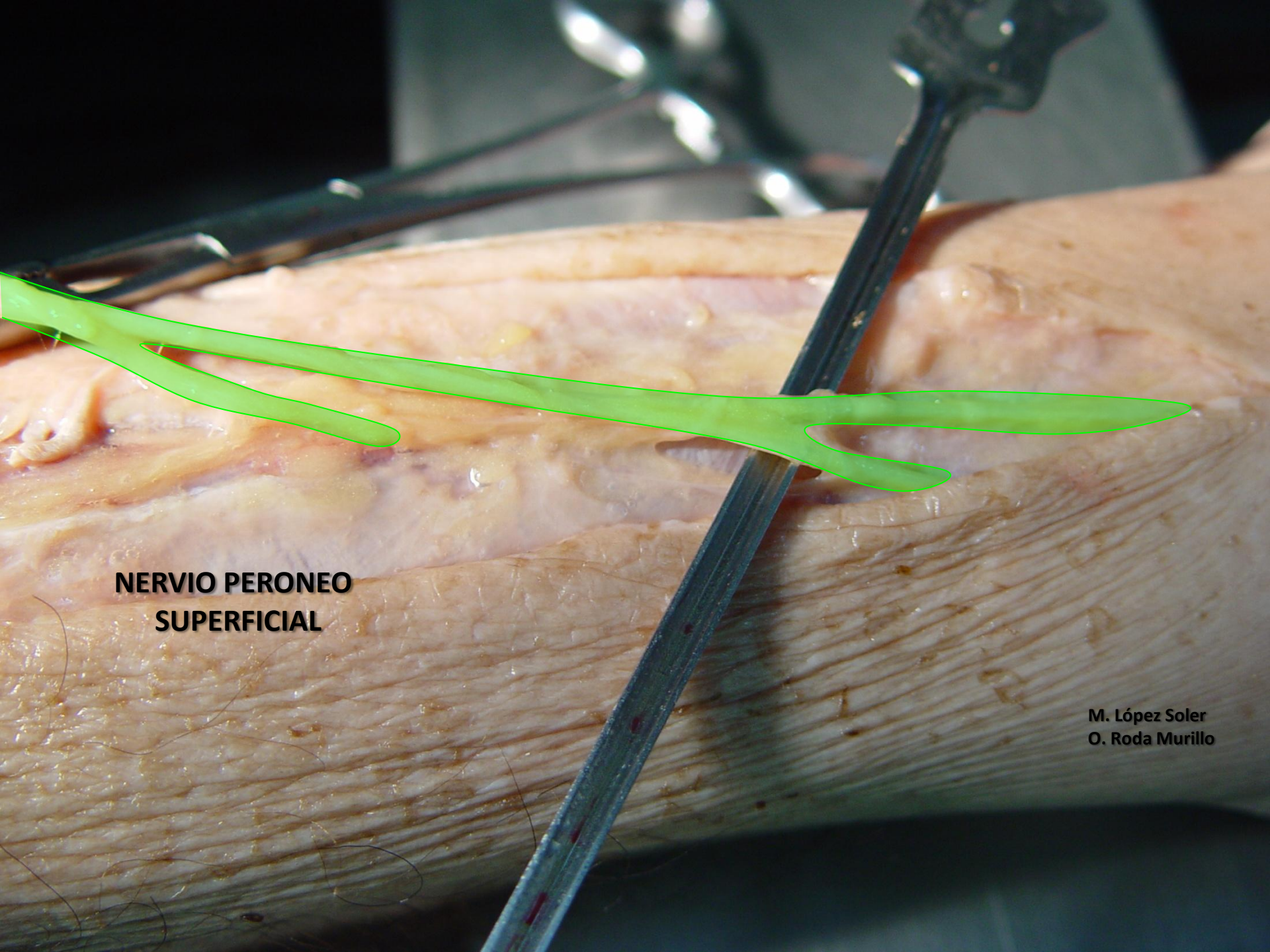
**NERVIO PERONEO
SUPERFICIAL**

**NERVIOS DIGITALES
(PERONEO SUPERFICIAL)**

M. López Soler
O. Roda Murillo

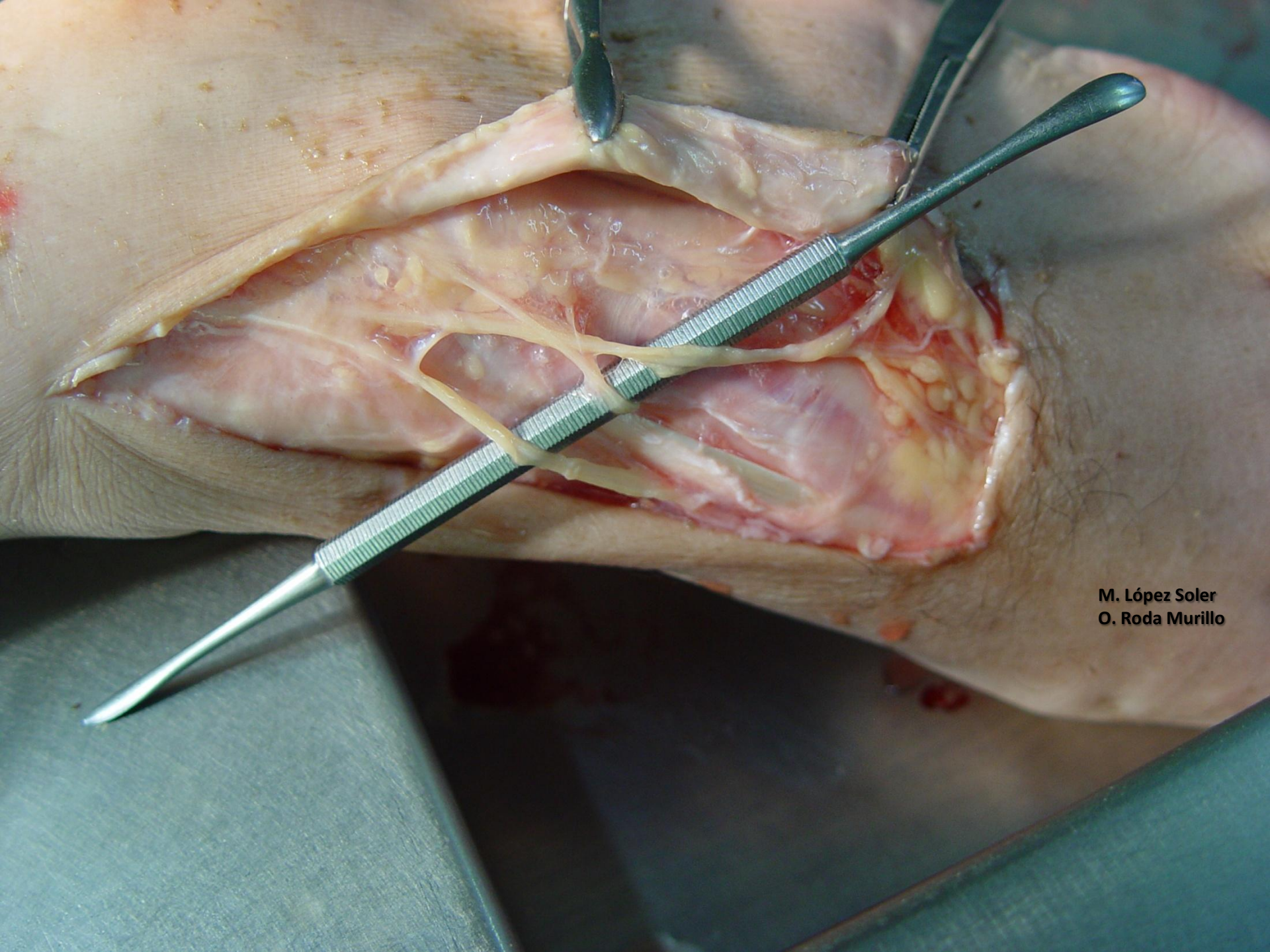


M. López Soler
O. Roda Murillo

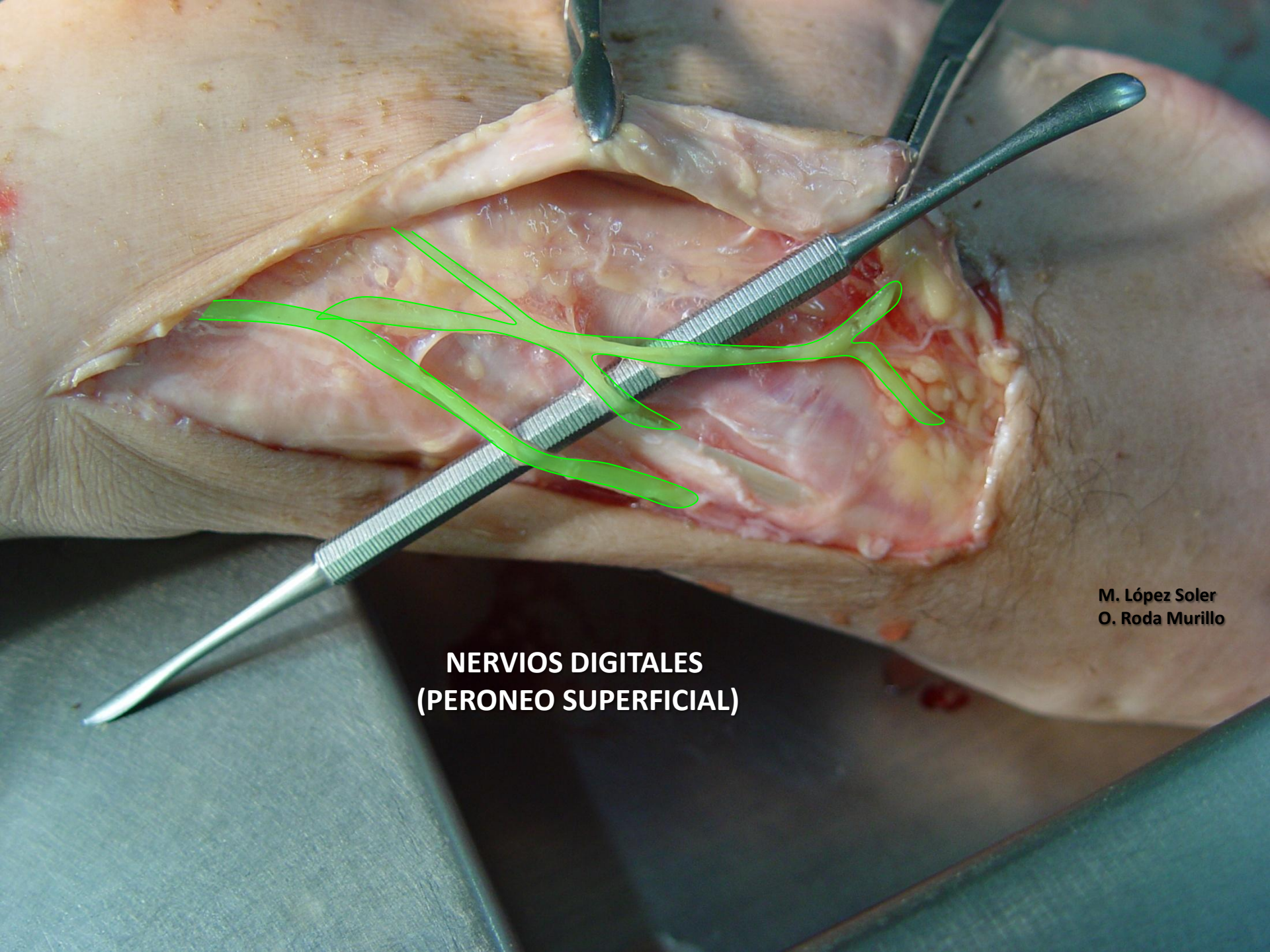


**NERVIO PERONEO
SUPERFICIAL**

M. López Soler
O. Roda Murillo

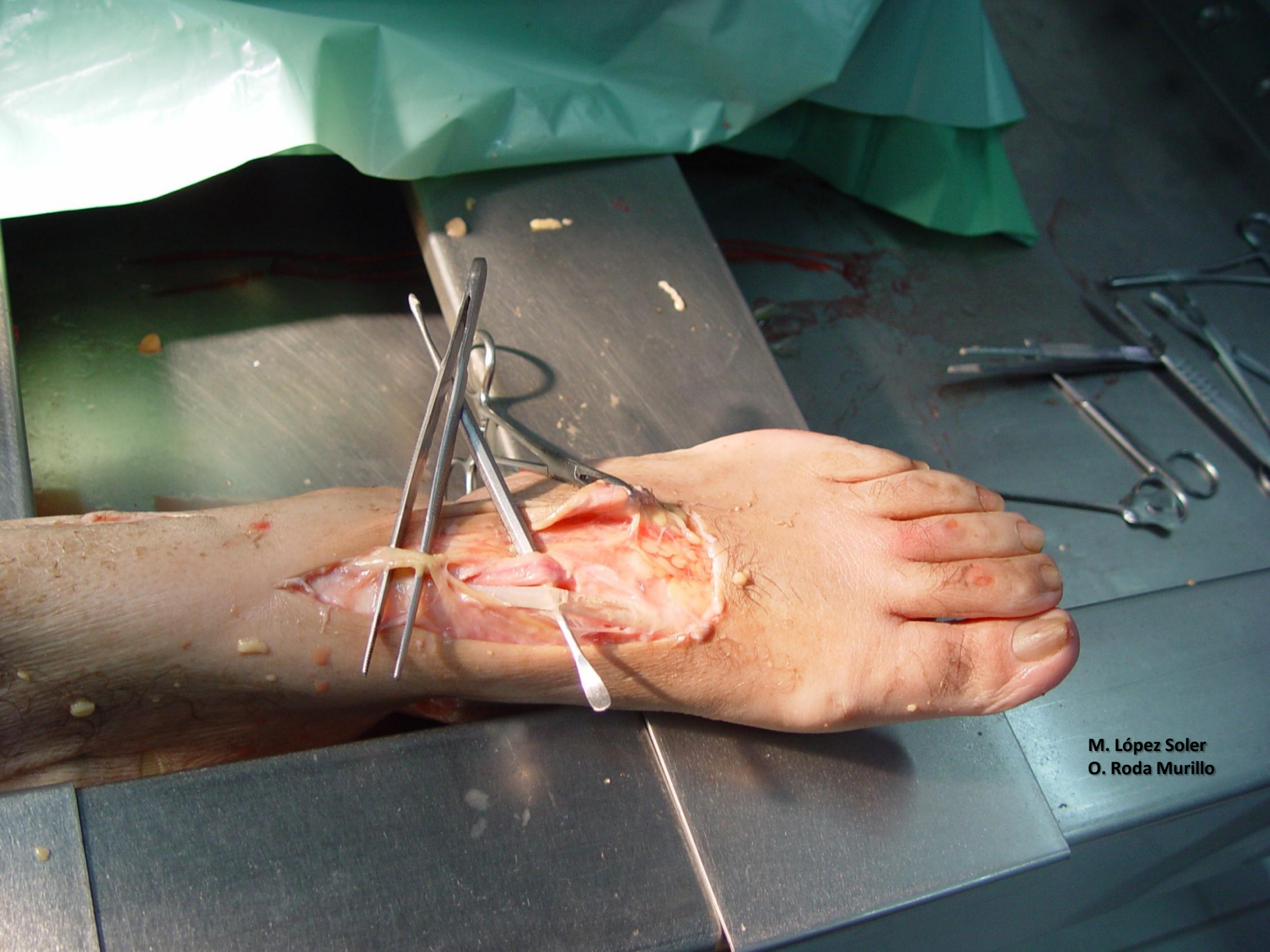

M. López Soler
O. Roda Murillo

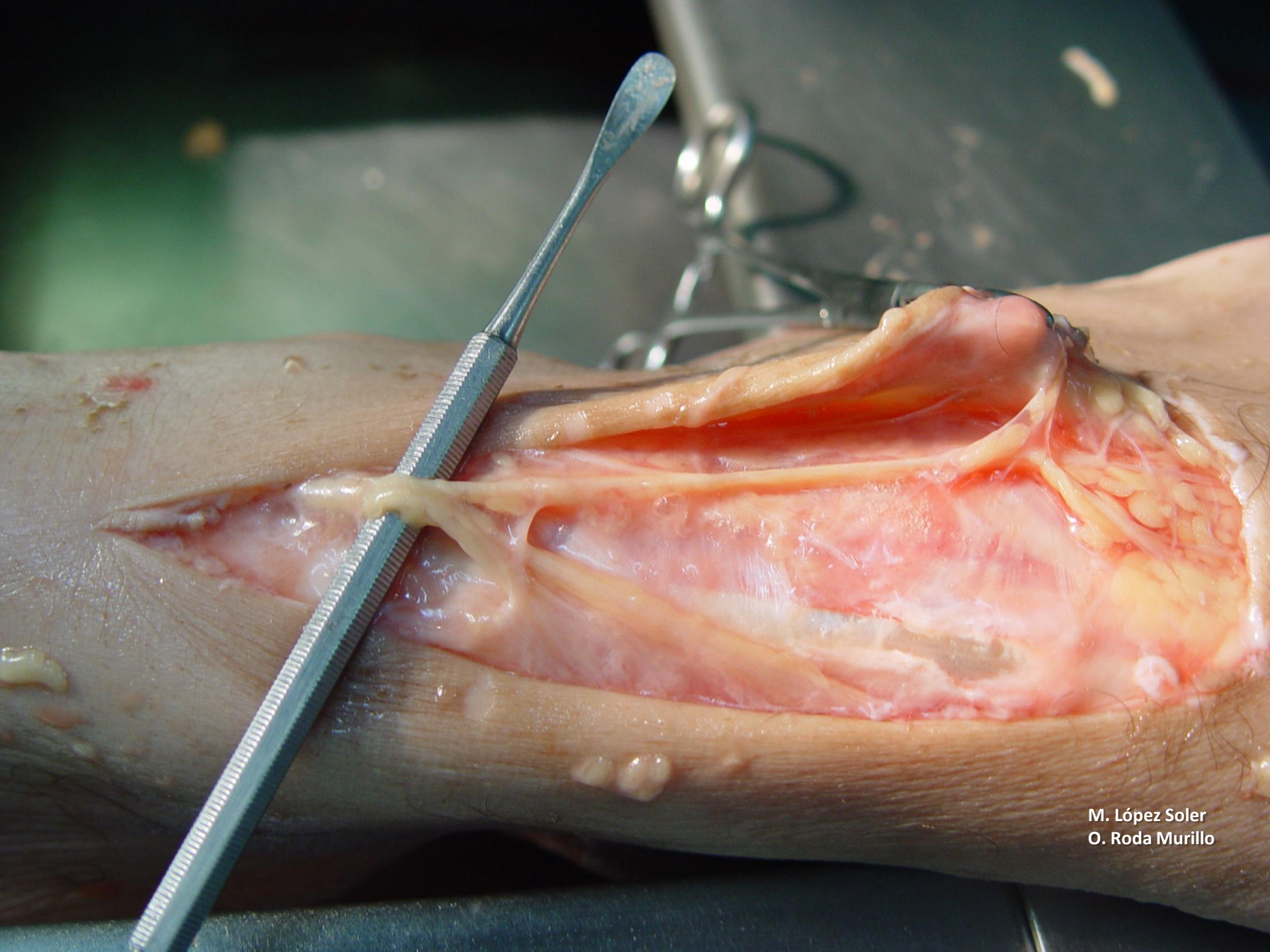


M. López Soler
O. Roda Murillo

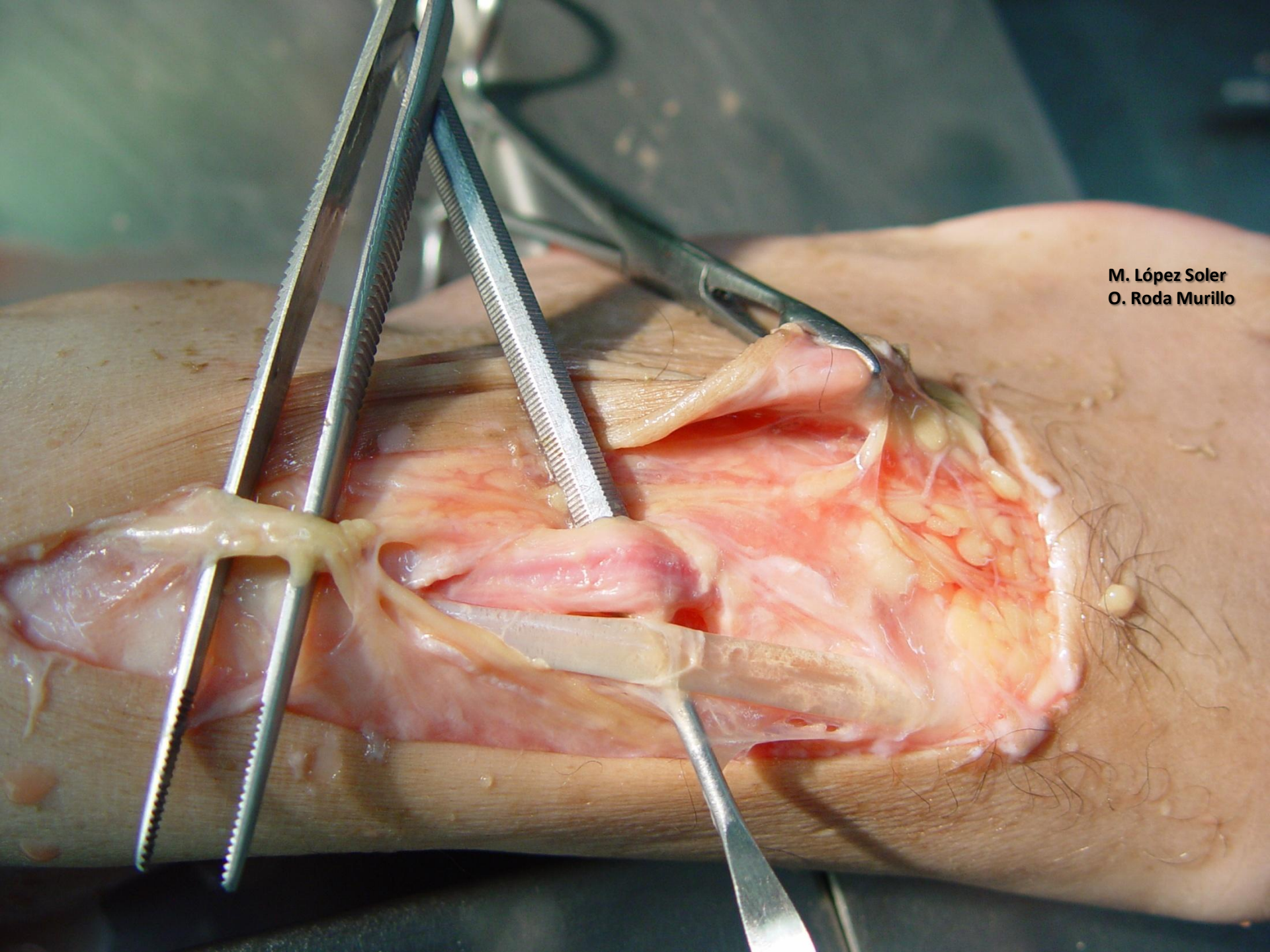
**NERVIOS DIGITALES
(PERONEO SUPERFICIAL)**



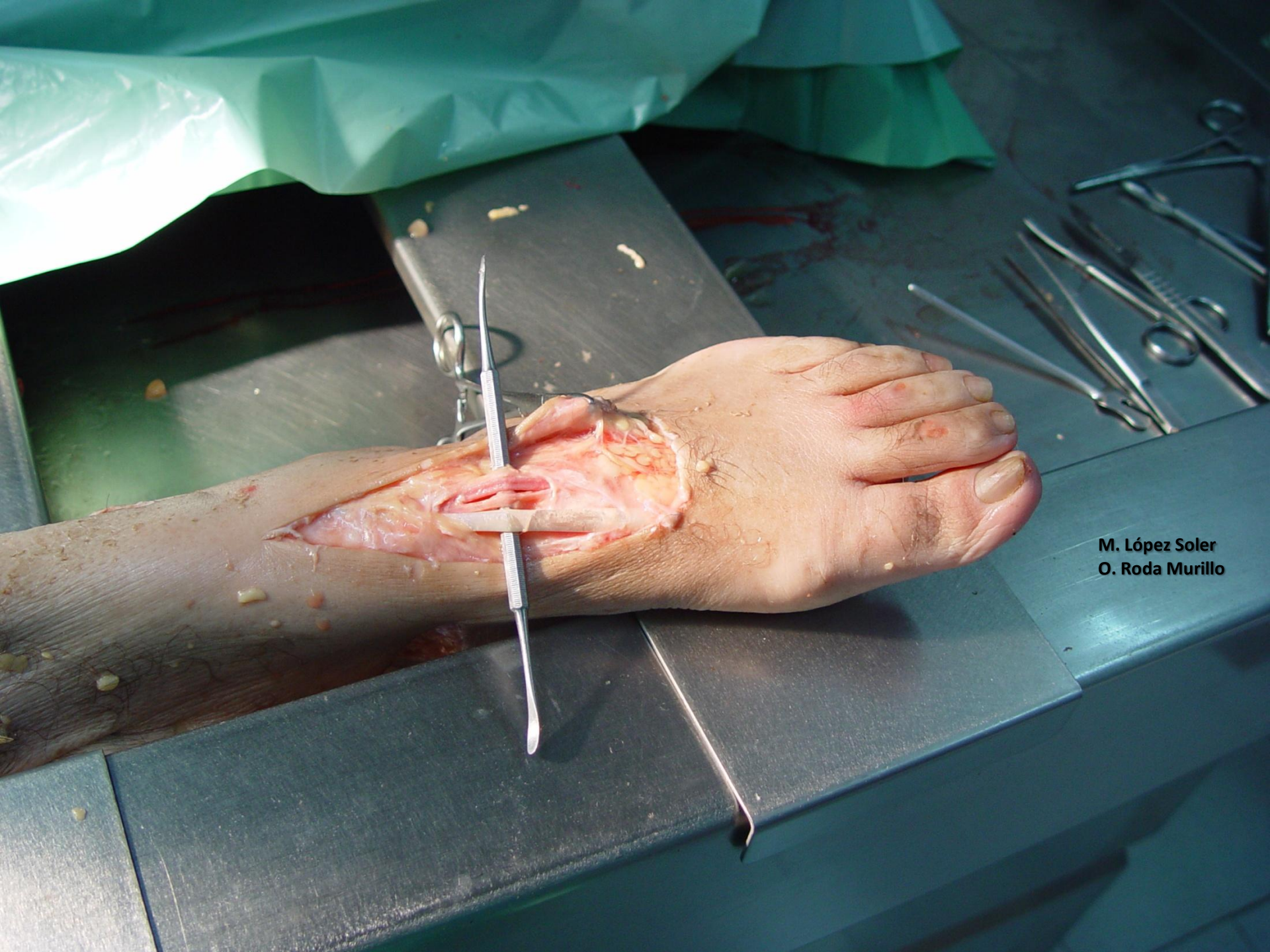
M. López Soler
O. Roda Murillo



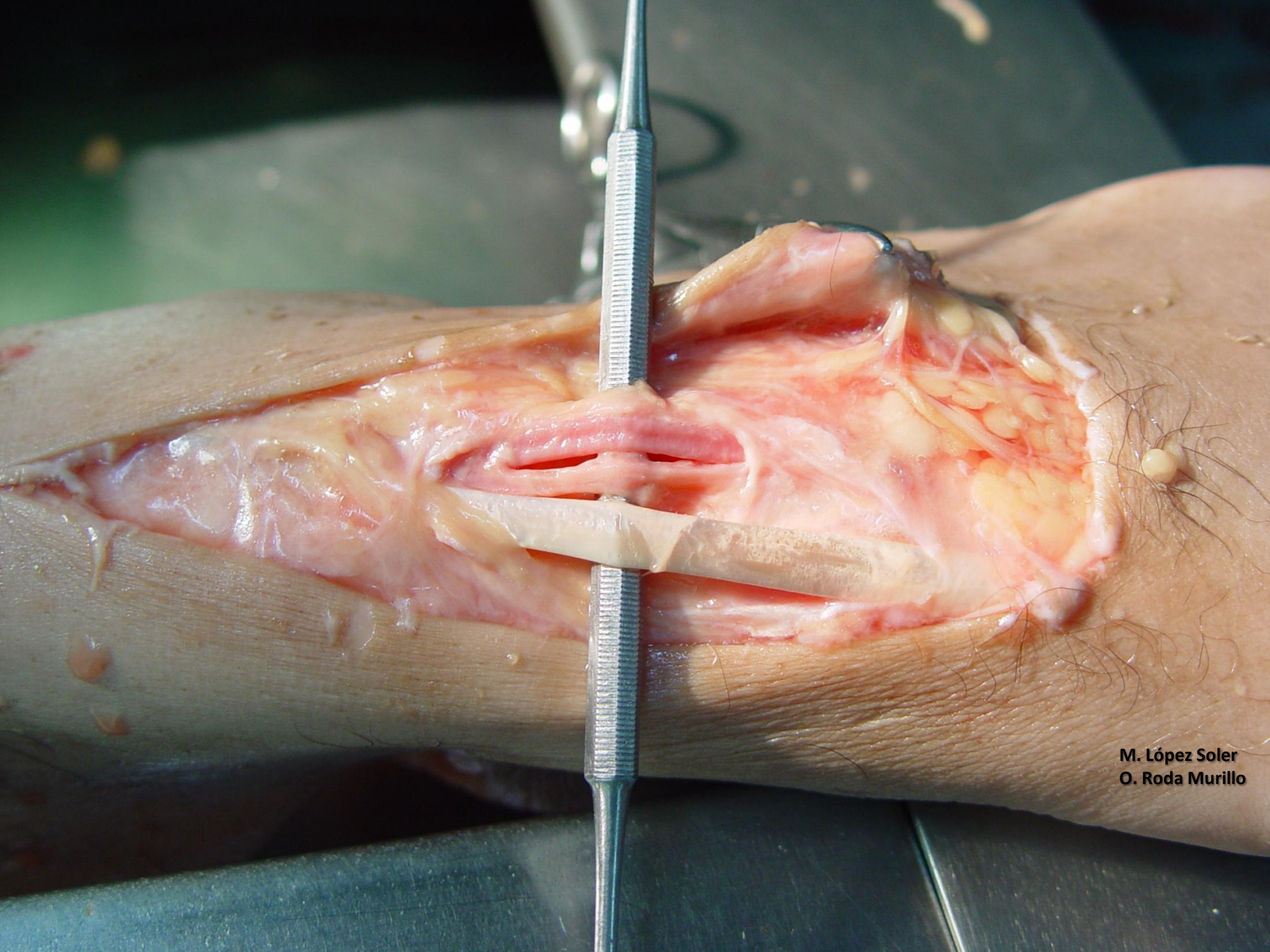M. López Soler
O. Roda Murillo



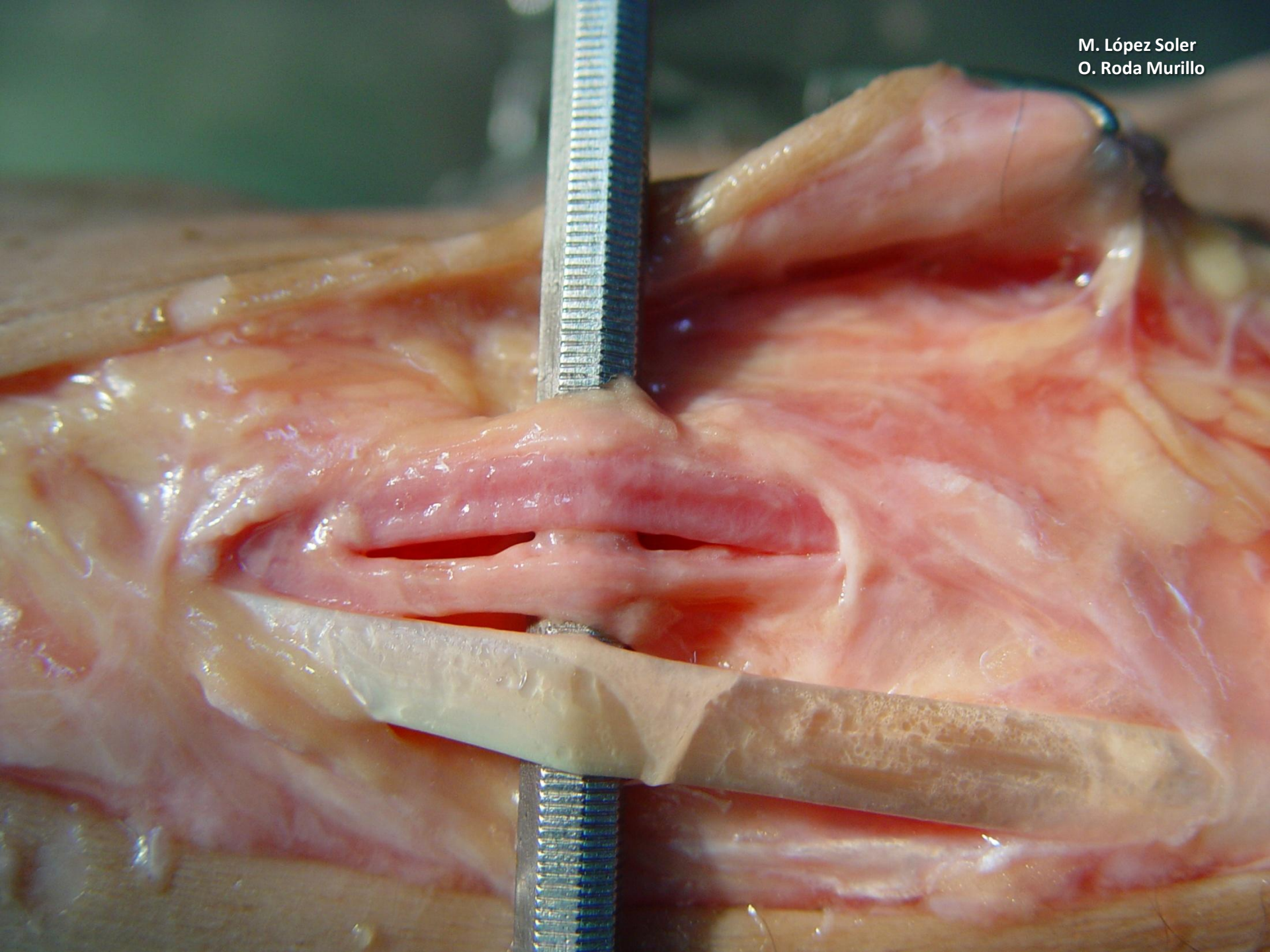
M. López Soler
O. Roda Murillo



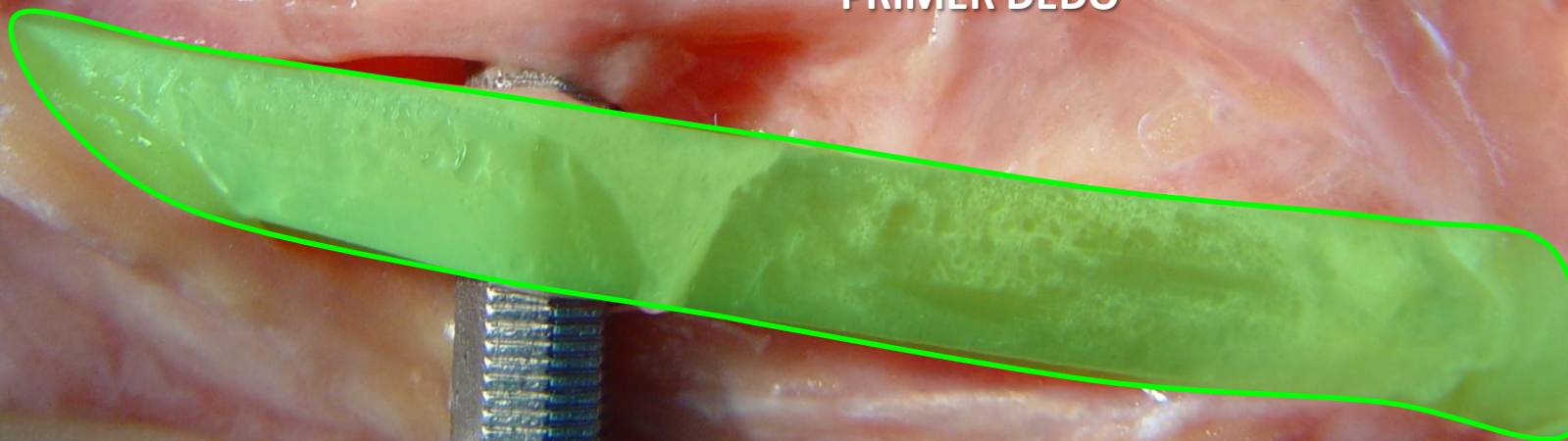
M. López Soler
O. Roda Murillo



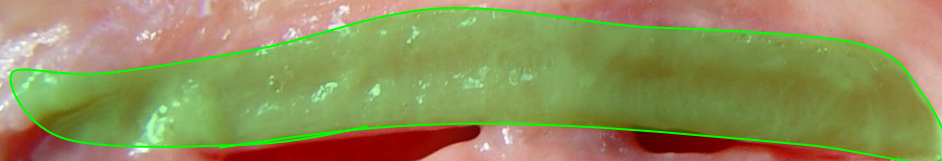M. López Soler
O. Roda Murillo



TENDÓN EXTENSOR LARGO
PRIMER DEDO

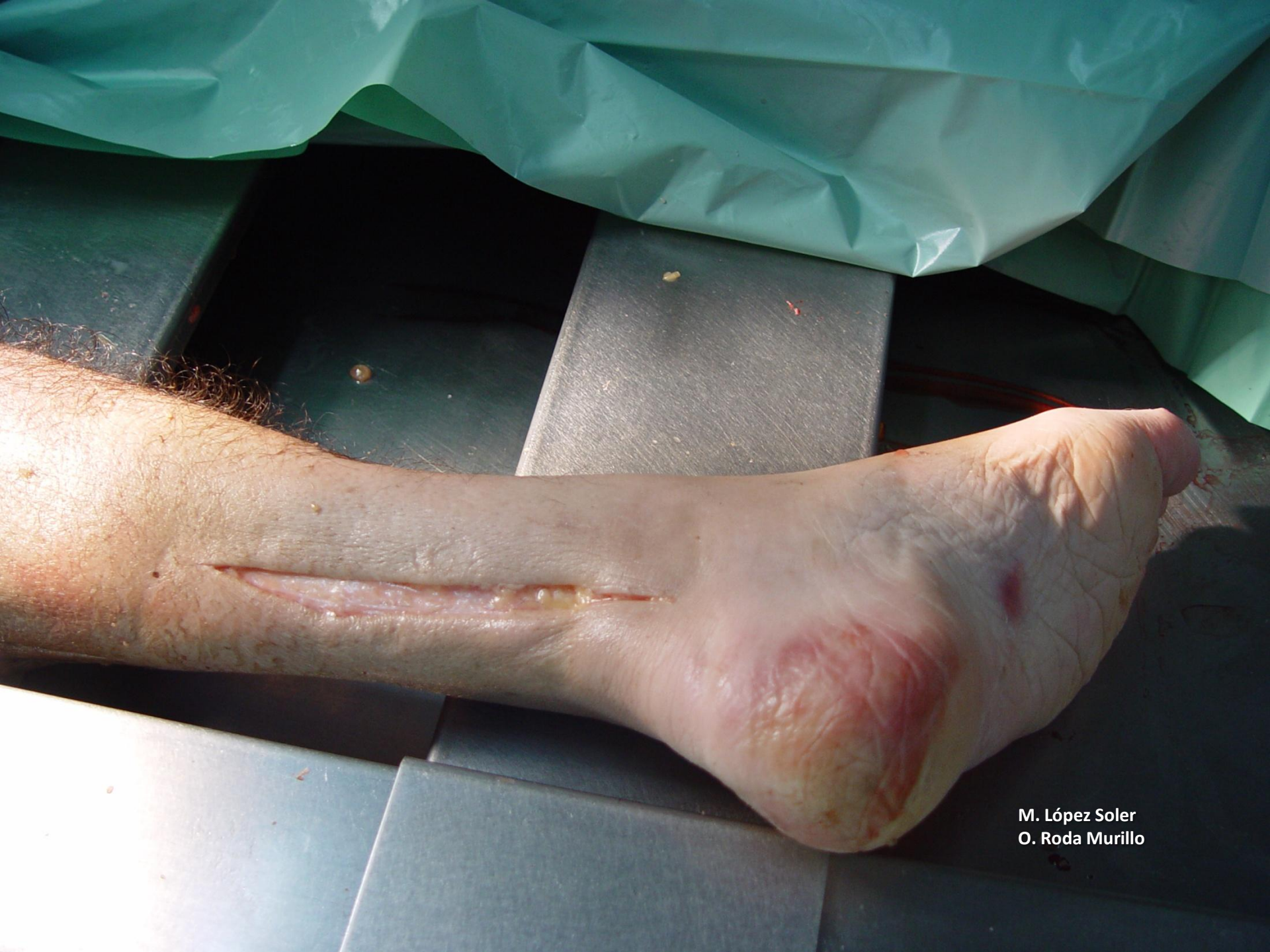

ARTERIA DORSAL
DEL PIE
(PEDIA)



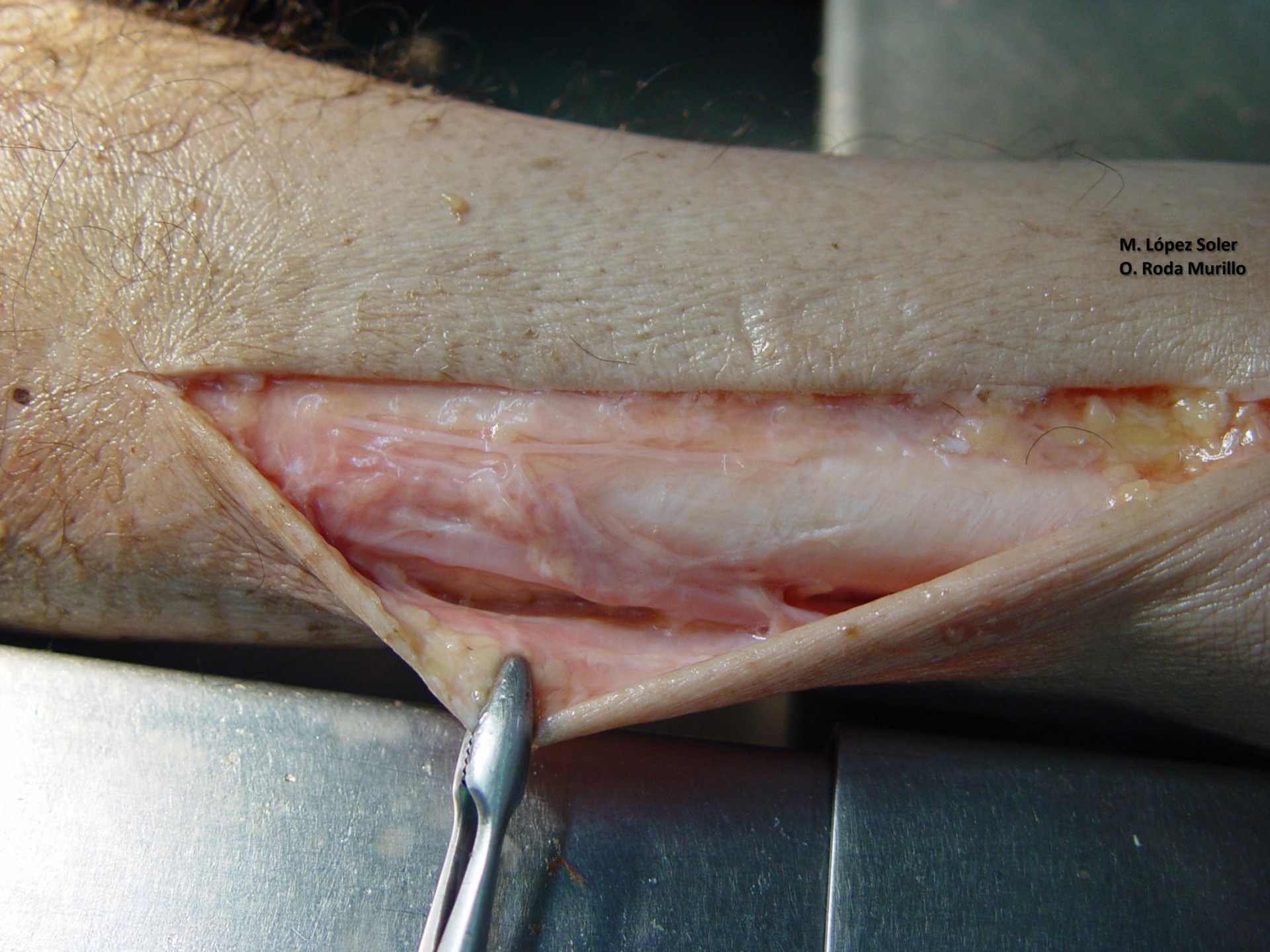
NERVIO PERONEO PROFUNDO
(TIBIAL ANTERIOR)



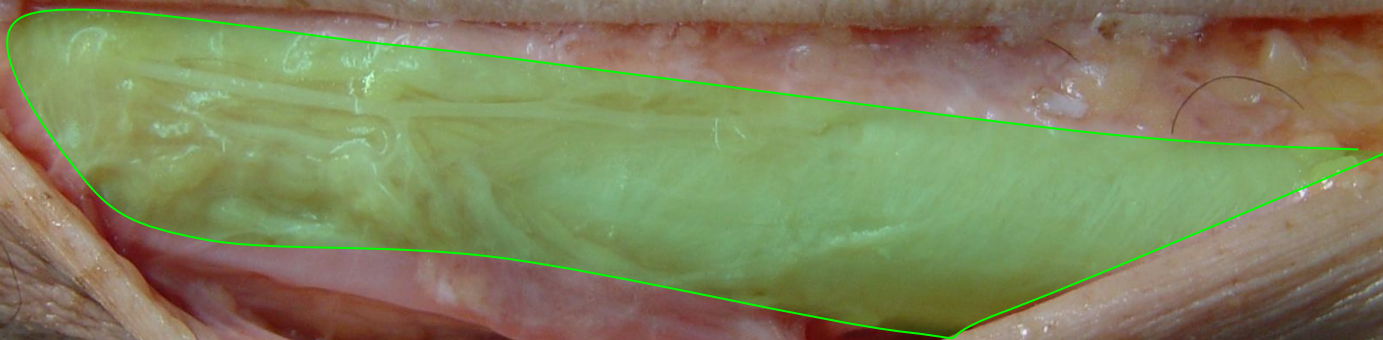


M. López Soler
O. Roda Murillo

M. López Soler
O. Roda Murillo

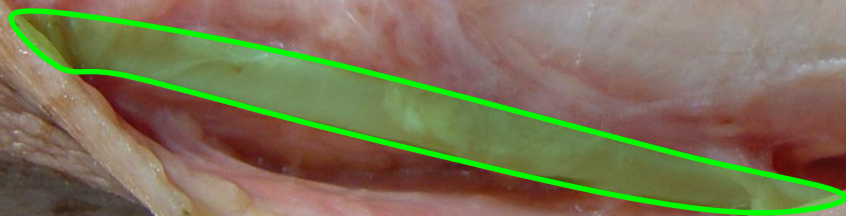


M. López Soler
O. Roda Murillo

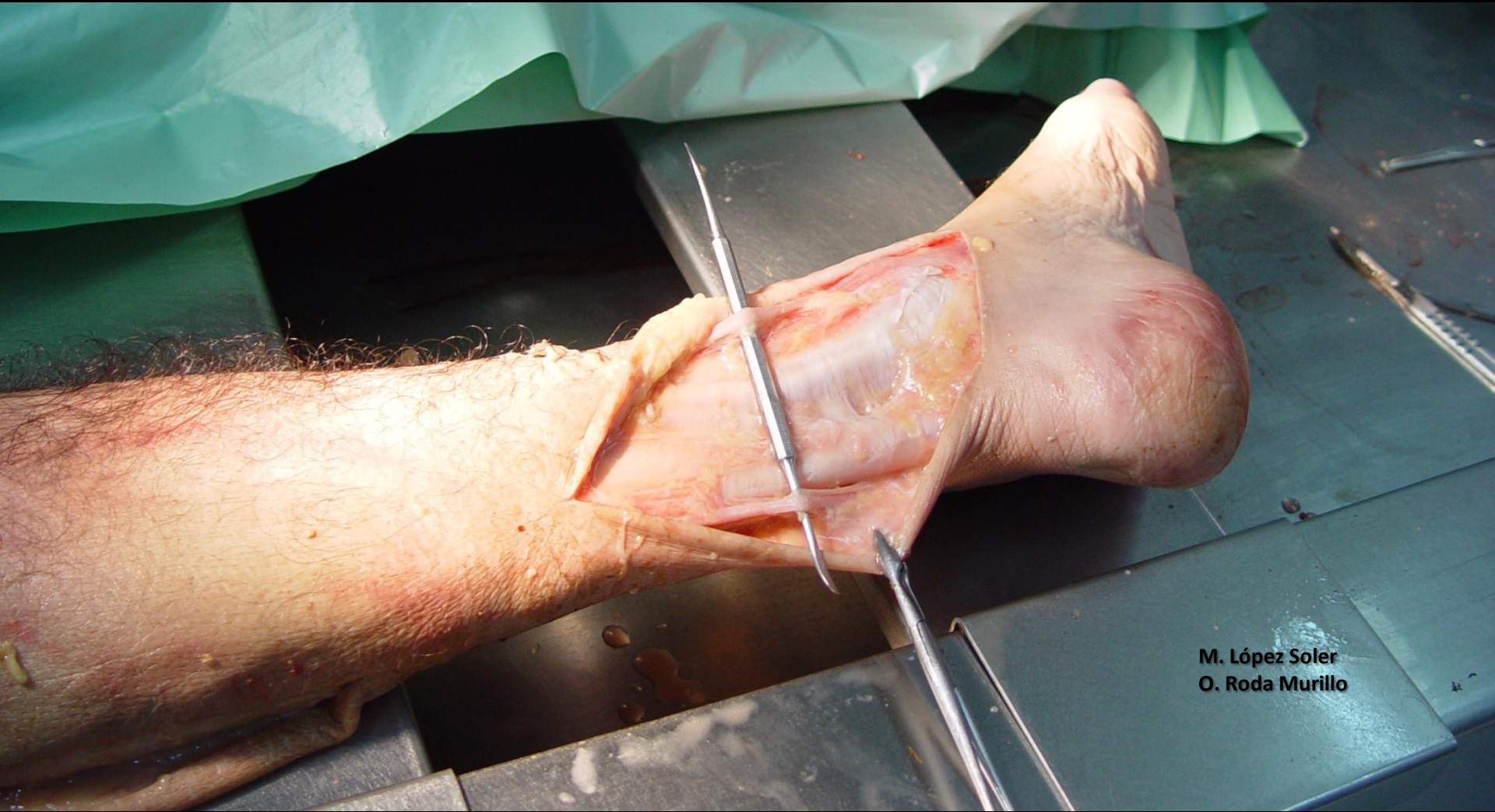

TENDÓN DE AQUILES

M. López Soler
O. Roda Murillo

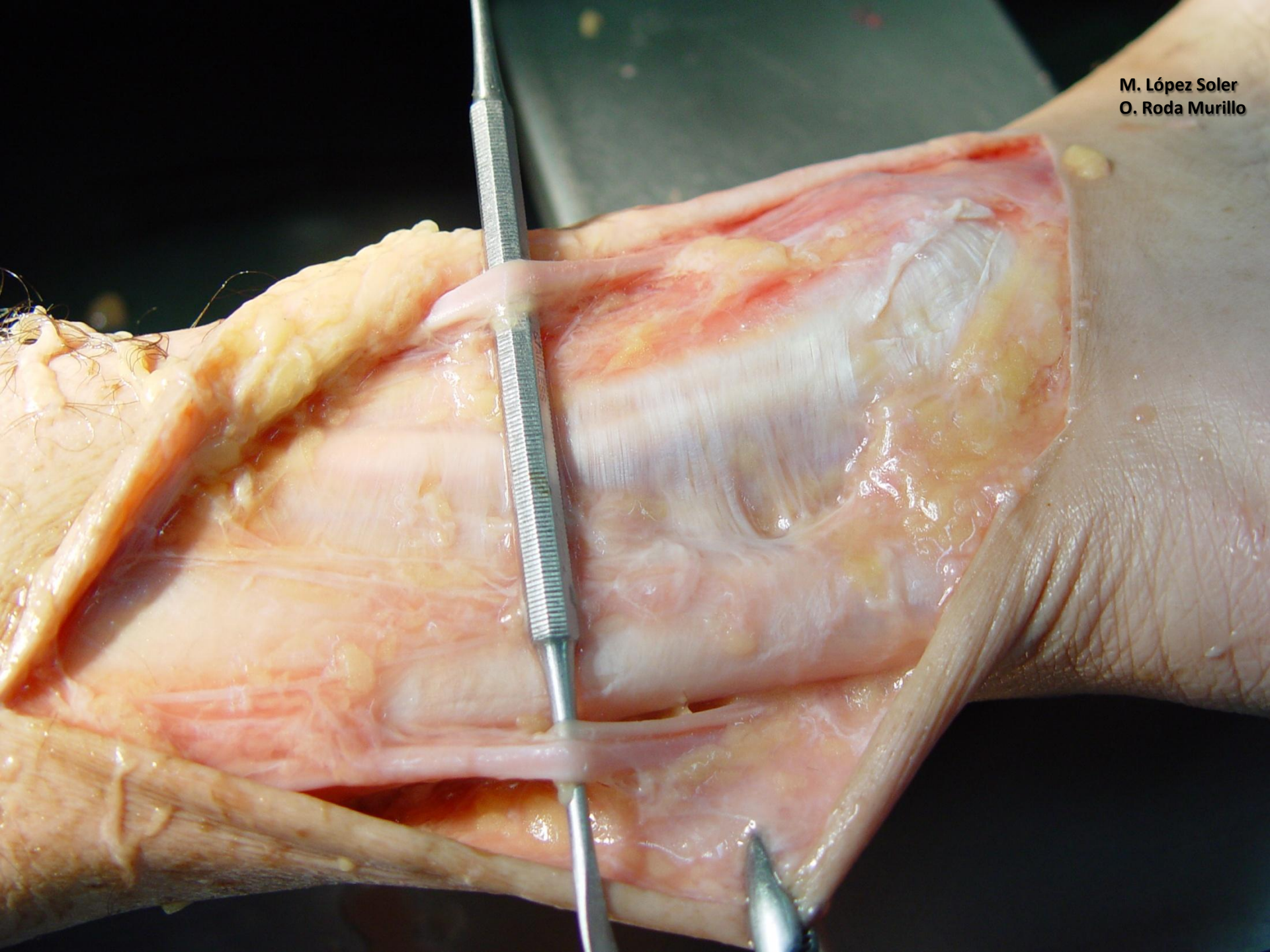


**VENA SAFENA EXTERNA
(MENOR O PARVA)**

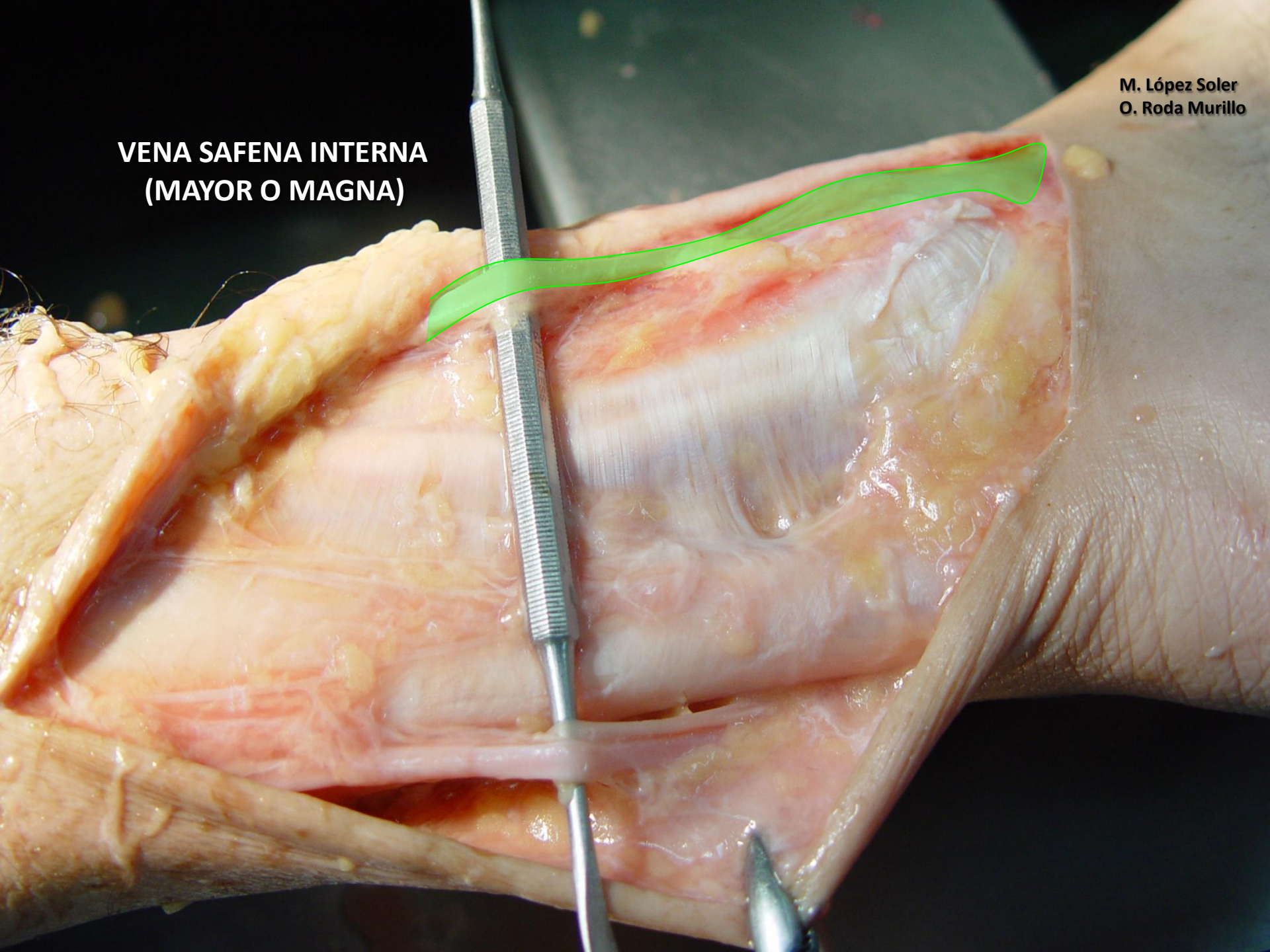


M. López Soler
O. Roda Murillo

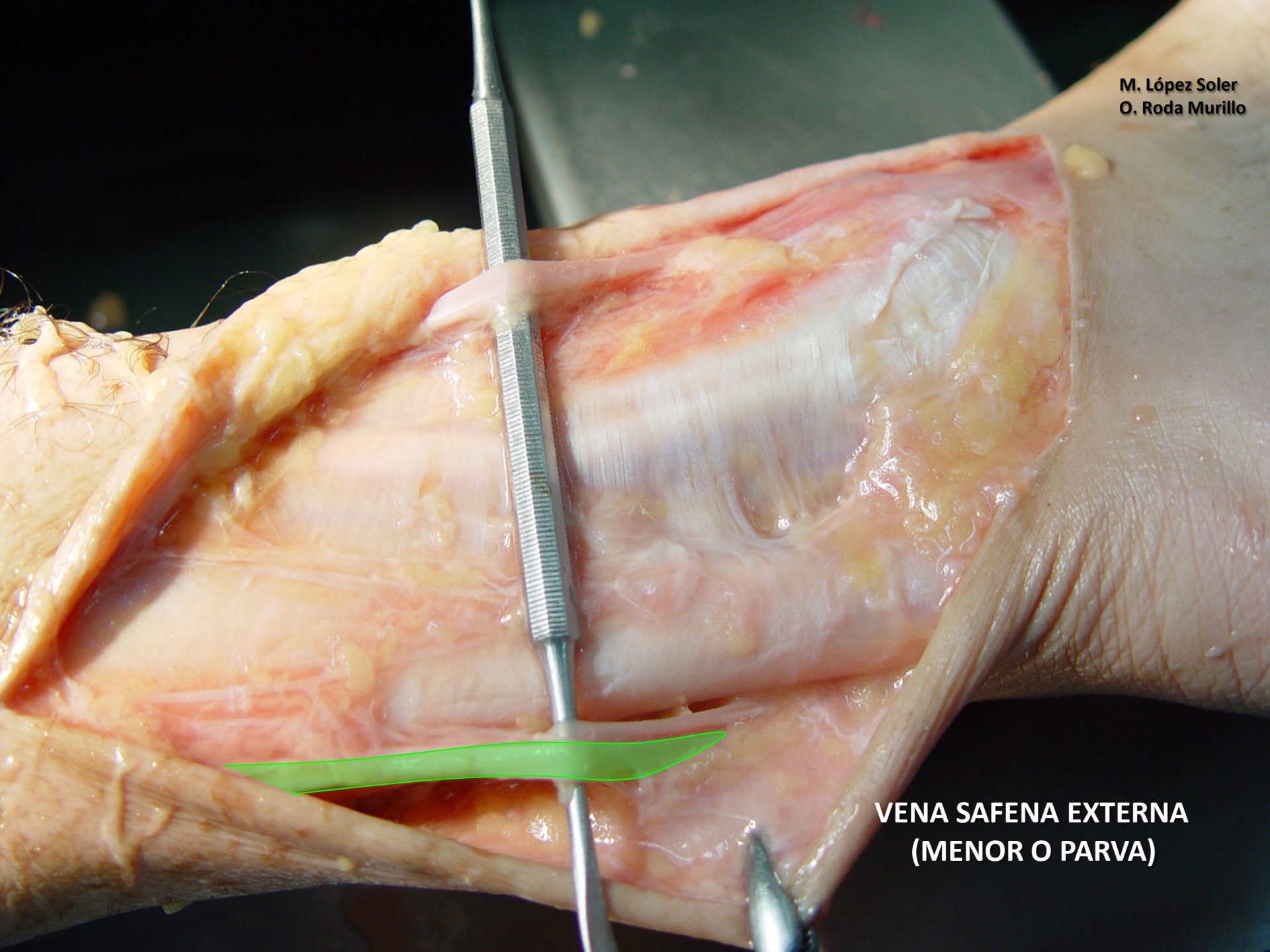M. López Soler
O. Roda Murillo



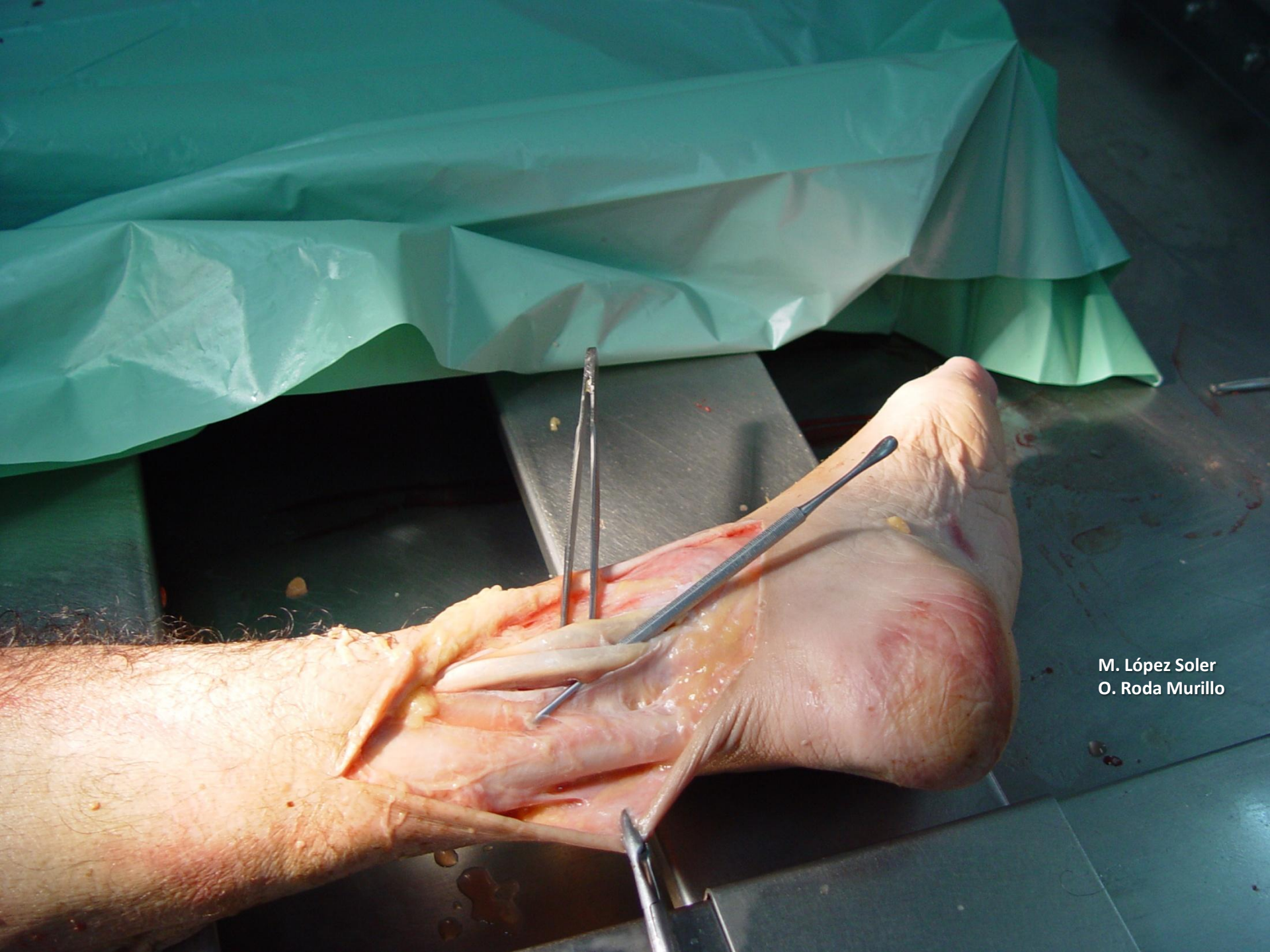**VENA SAFENA INTERNA
(MAYOR O MAGNA)**



M. López Soler
O. Roda Murillo

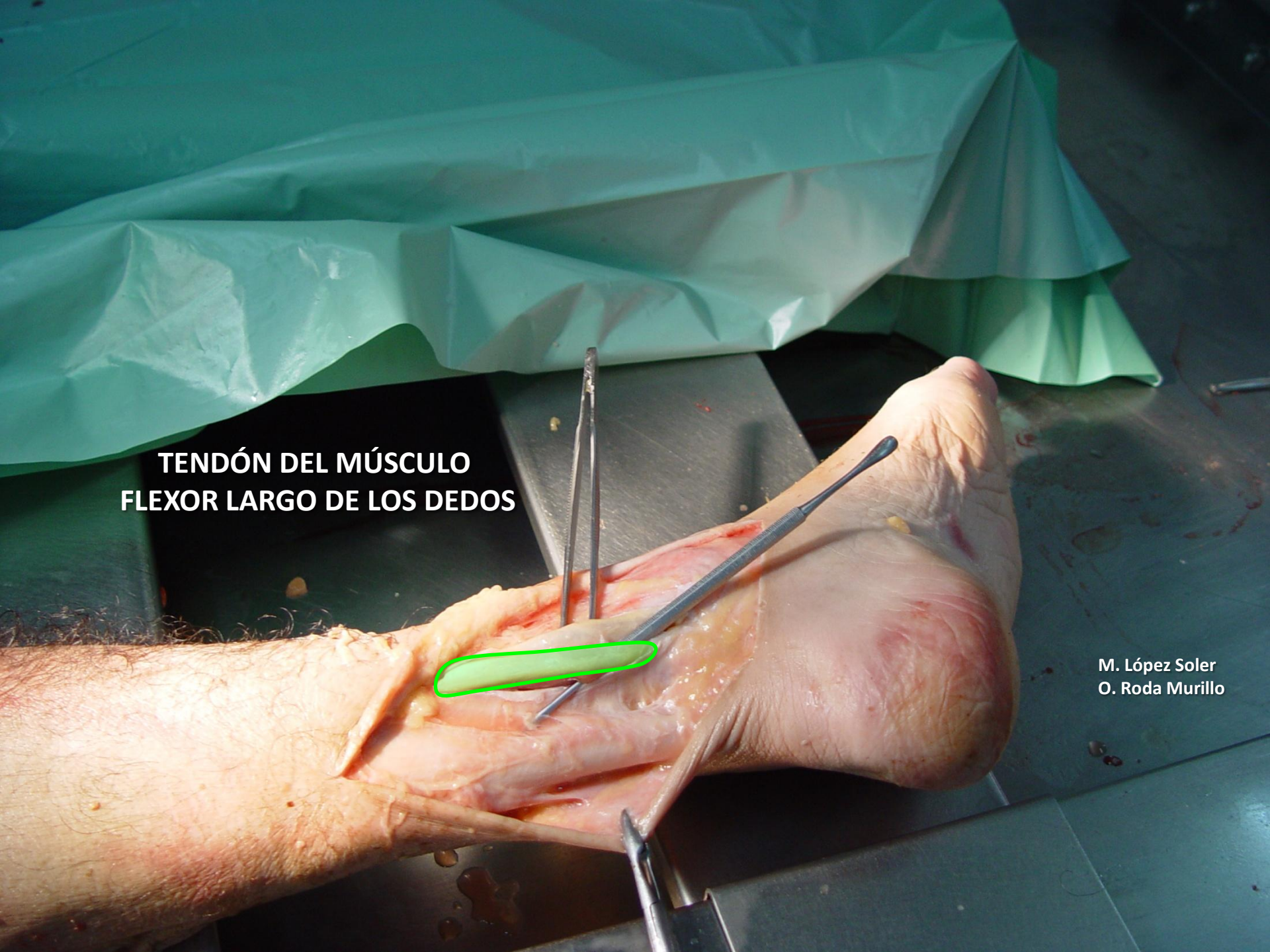

**VENA SAFENA EXTERNA
(MENOR O PARVA)**



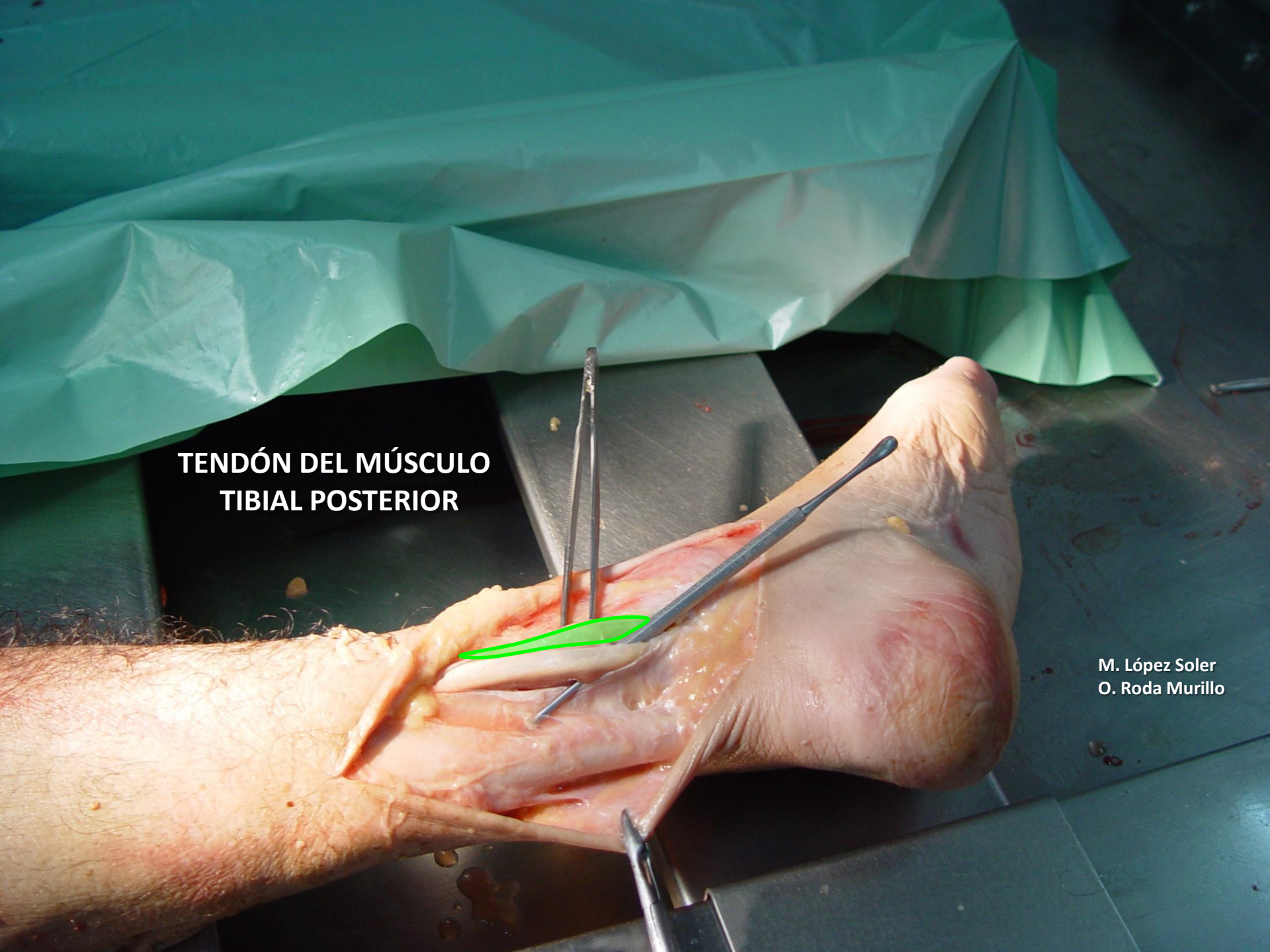
M. López Soler
O. Roda Murillo

**TENDÓN DEL MÚSCULO
FLEXOR LARGO DE LOS DEDOS**

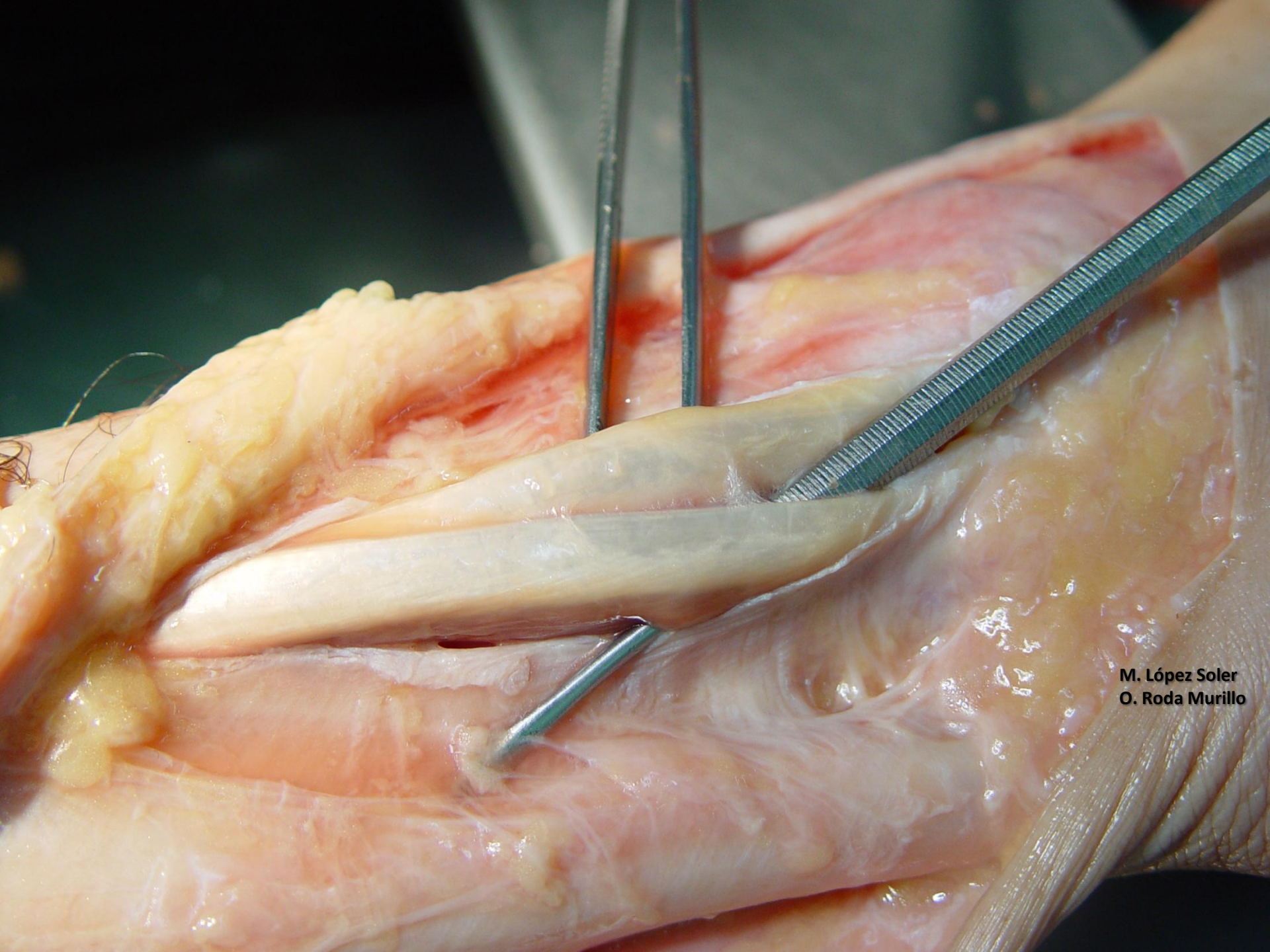


M. López Soler
O. Roda Murillo

**TENDÓN DEL MÚSCULO
TIBIAL POSTERIOR**

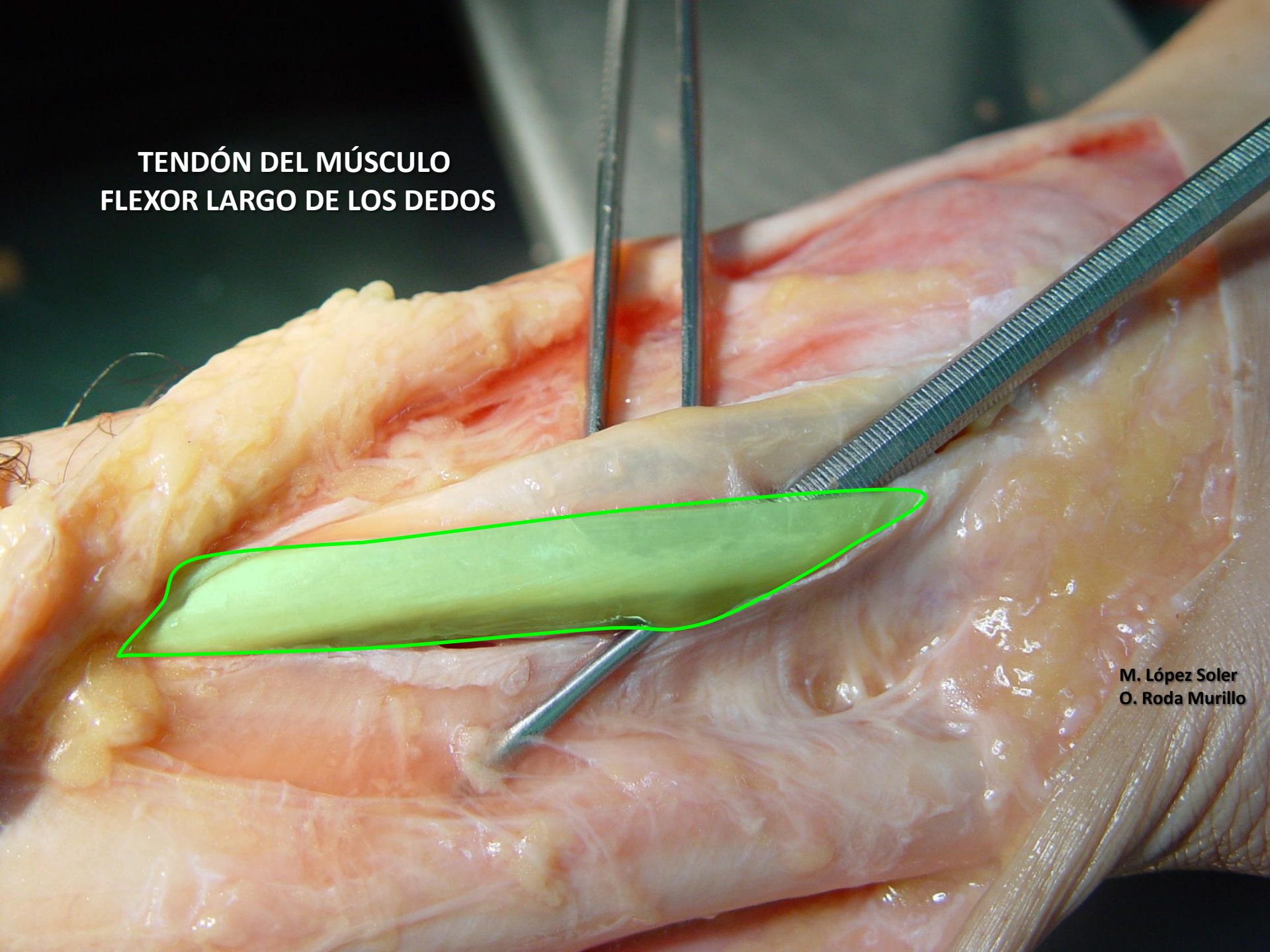


M. López Soler
O. Roda Murillo



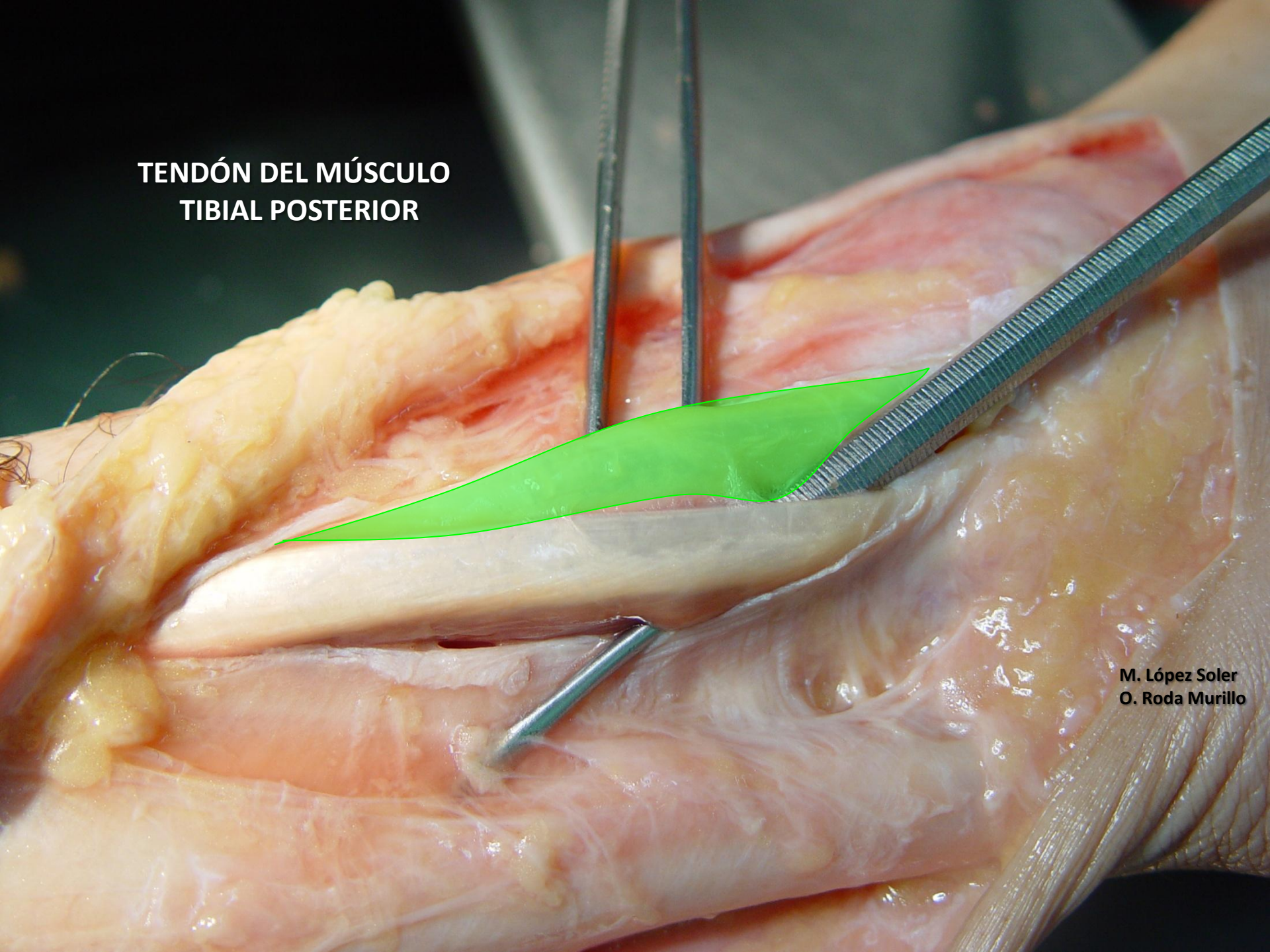M. López Soler
O. Roda Murillo

**TENDÓN DEL MÚSCULO
FLEXOR LARGO DE LOS DEDOS**

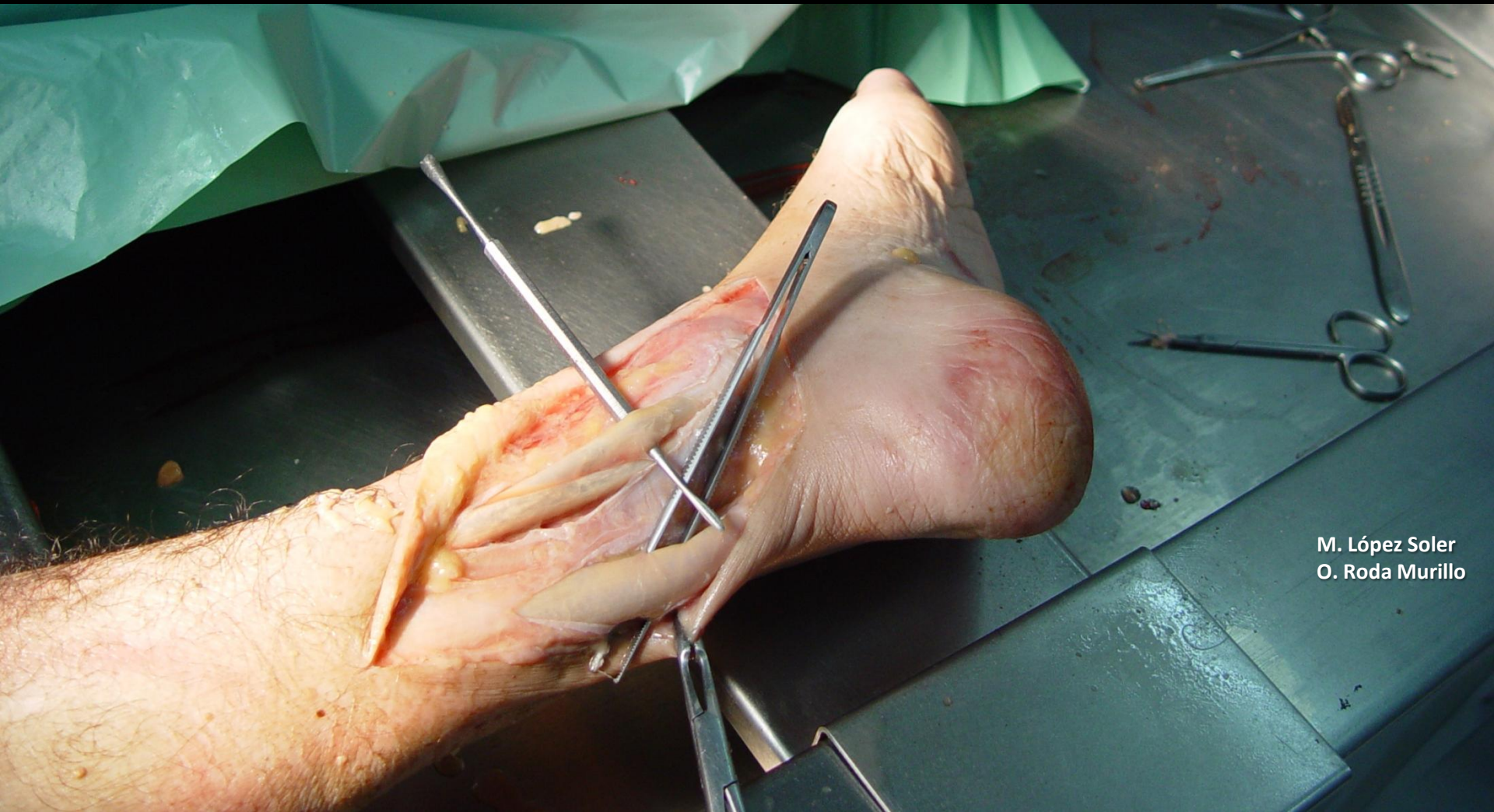


M. López Soler
O. Roda Murillo

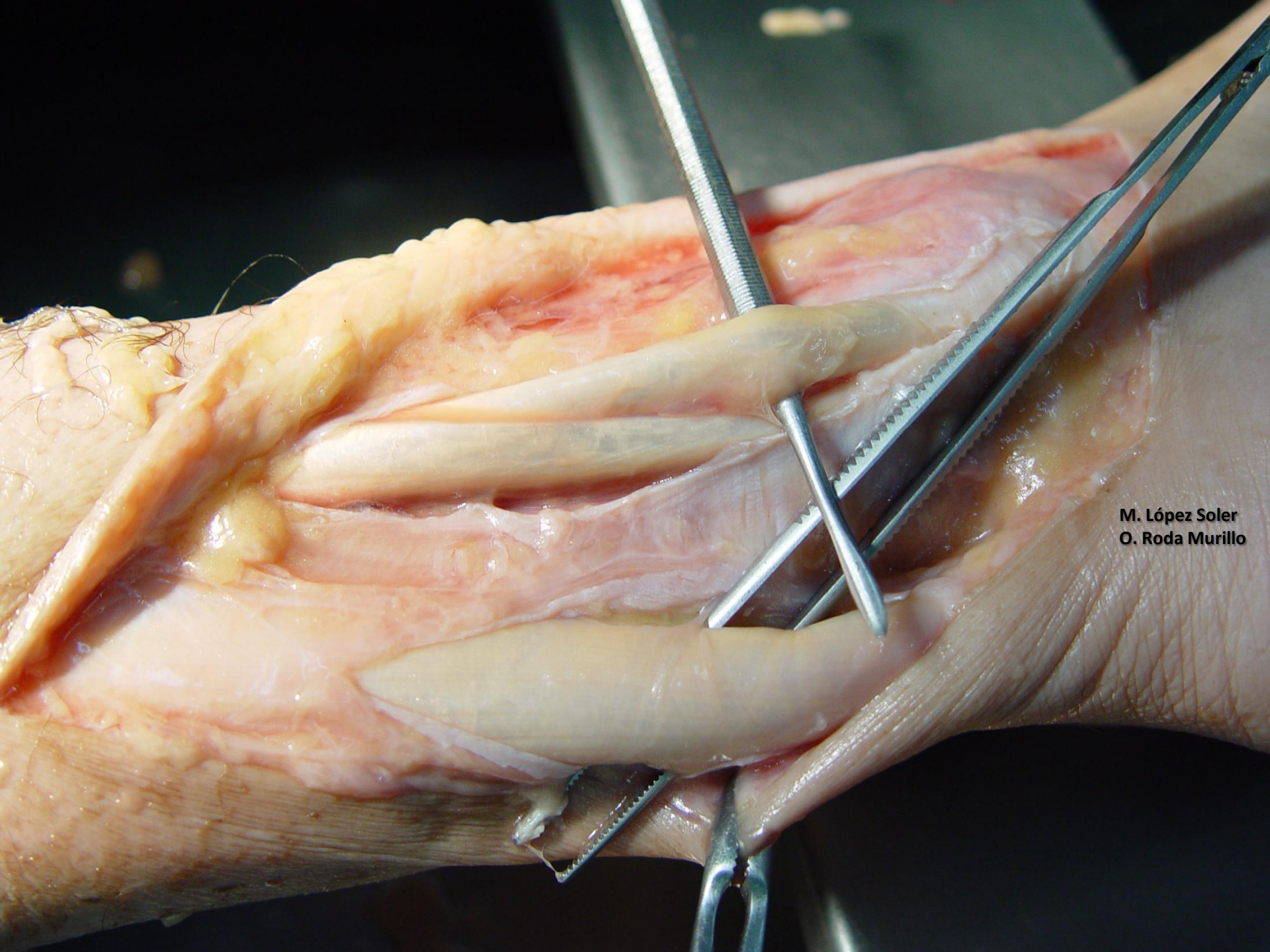
**TENDÓN DEL MÚSCULO
TIBIAL POSTERIOR**



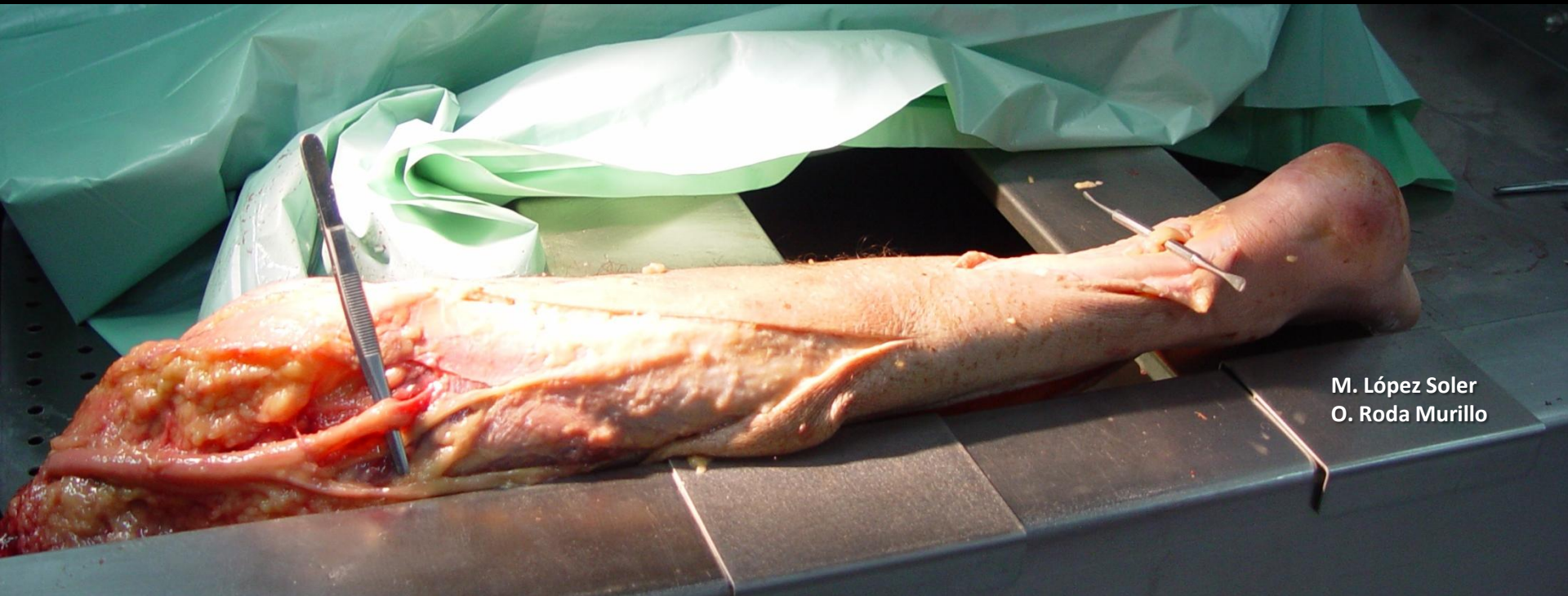**M. López Soler
O. Roda Murillo**



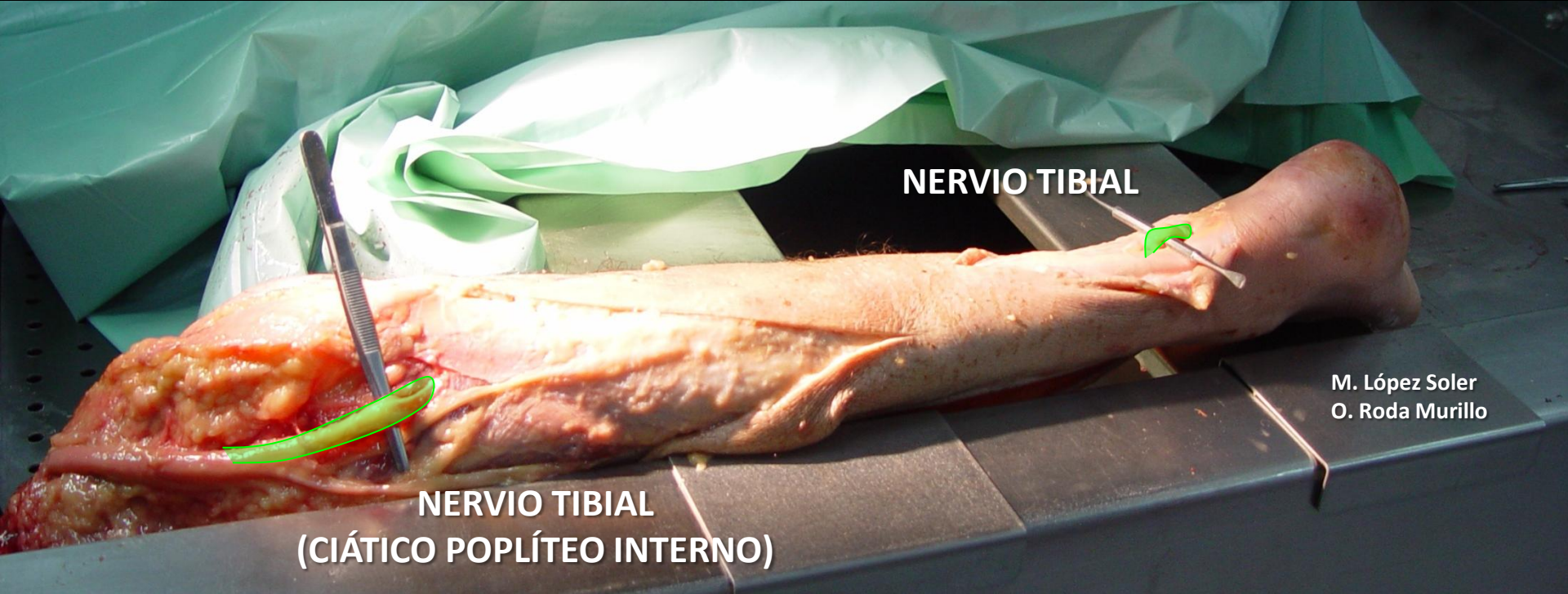
M. López Soler
O. Roda Murillo



M. López Soler
O. Roda Murillo



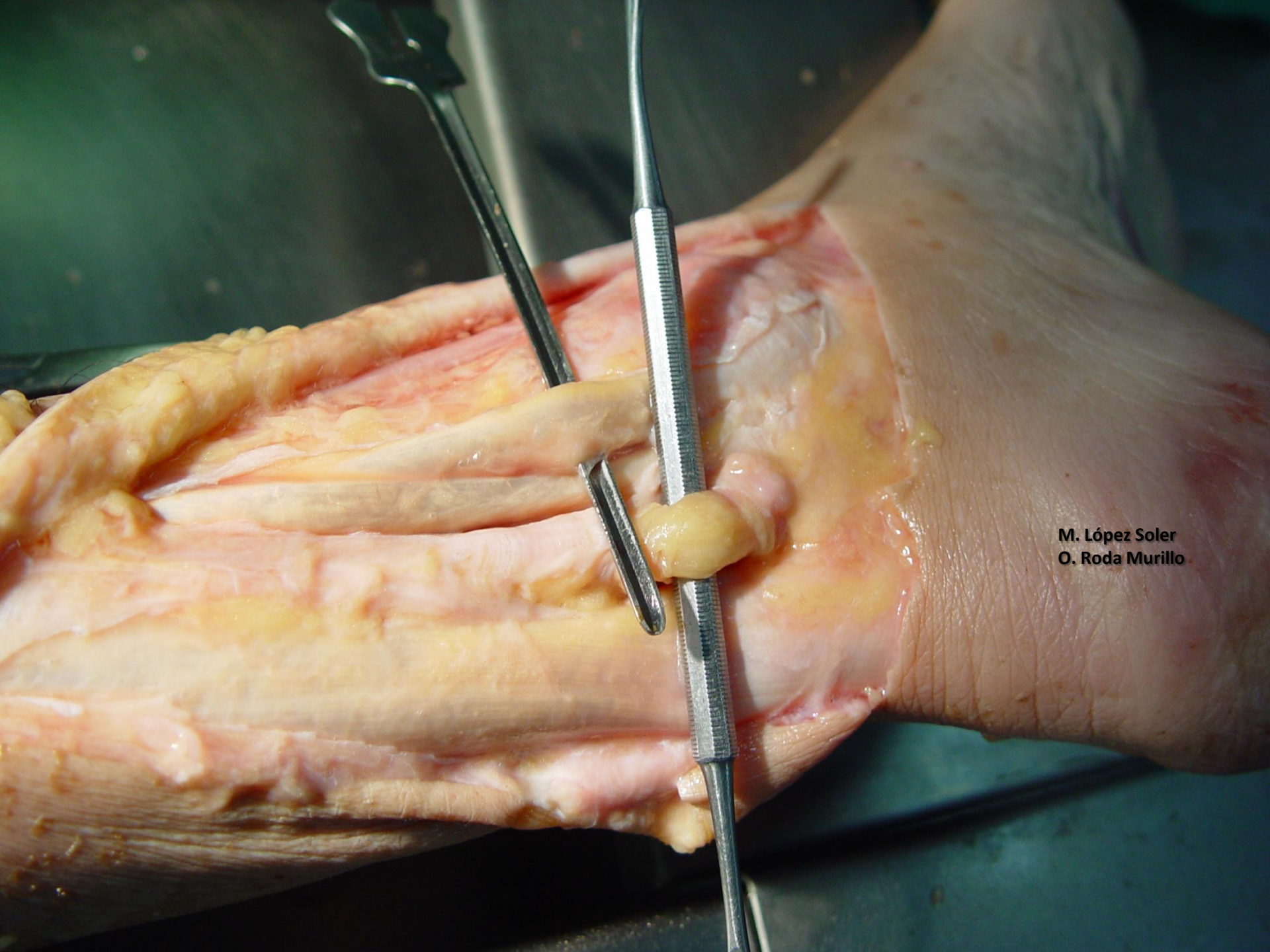
M. López Soler
O. Roda Murillo



NERVIO TIBIAL

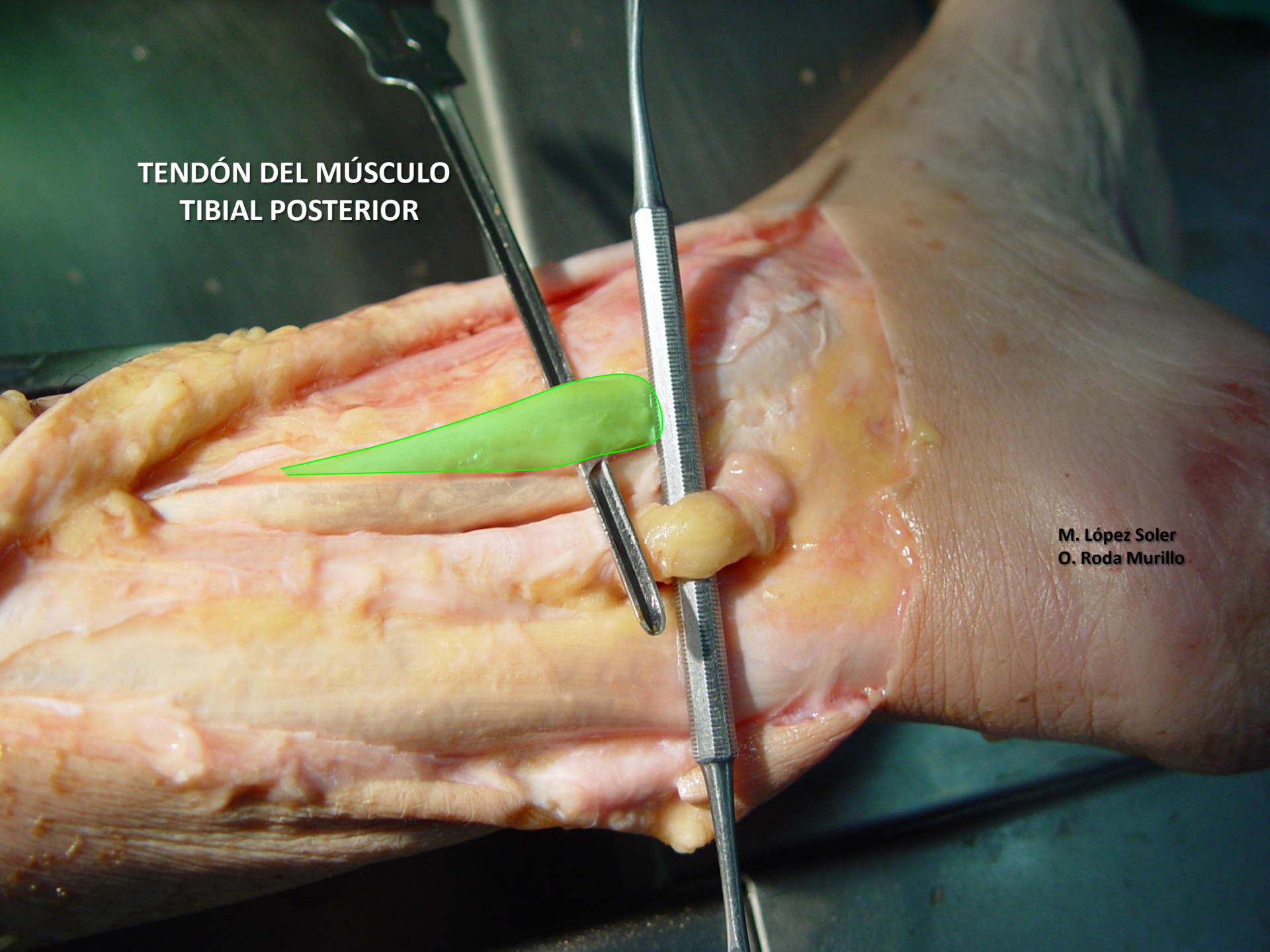
**NERVIO TIBIAL
(CIÁTICO POPLÍTEO INTERNO)**

M. López Soler
O. Roda Murillo



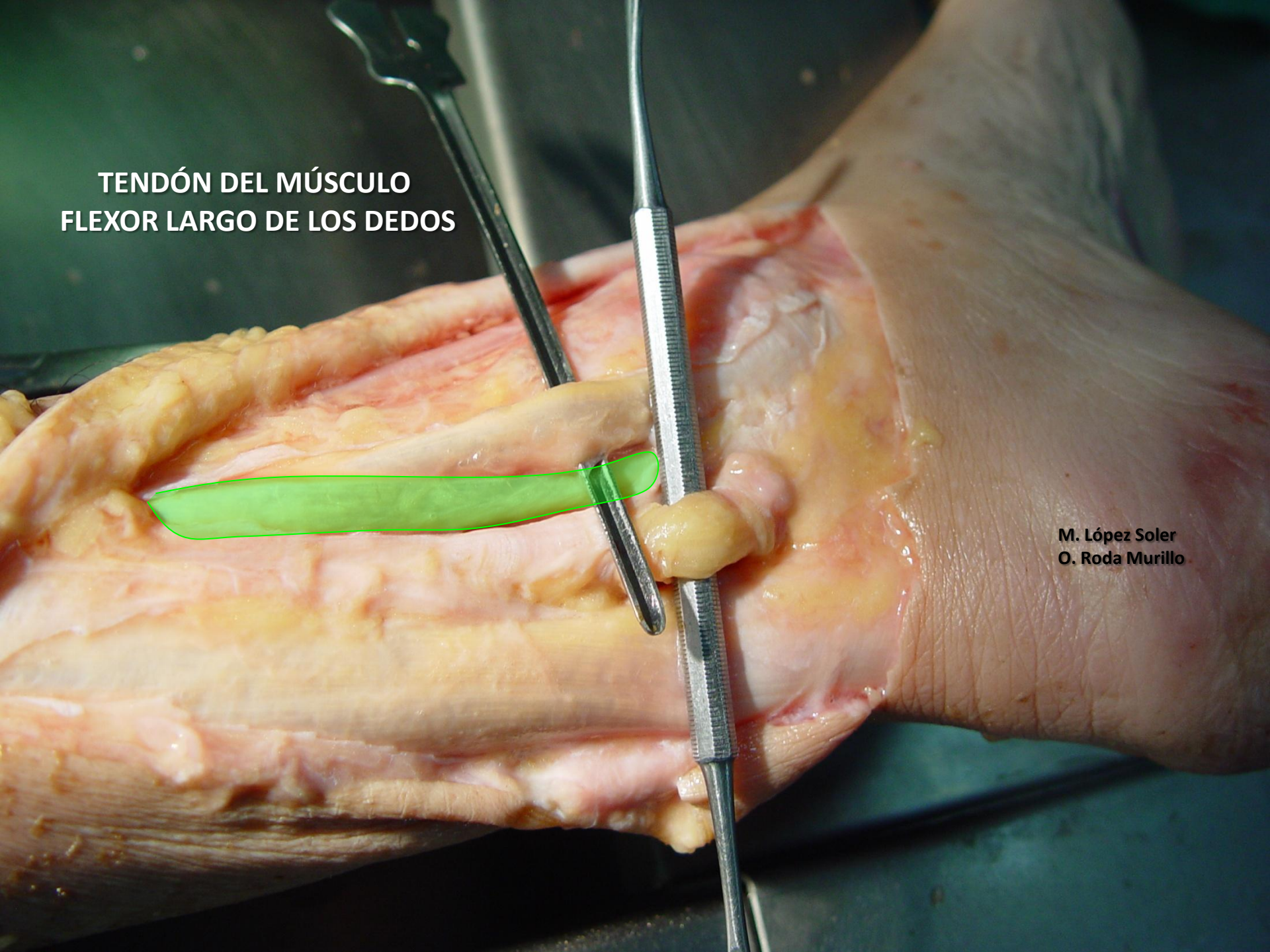
M. López Soler
O. Roda Murillo

**TENDÓN DEL MÚSCULO
TIBIAL POSTERIOR**

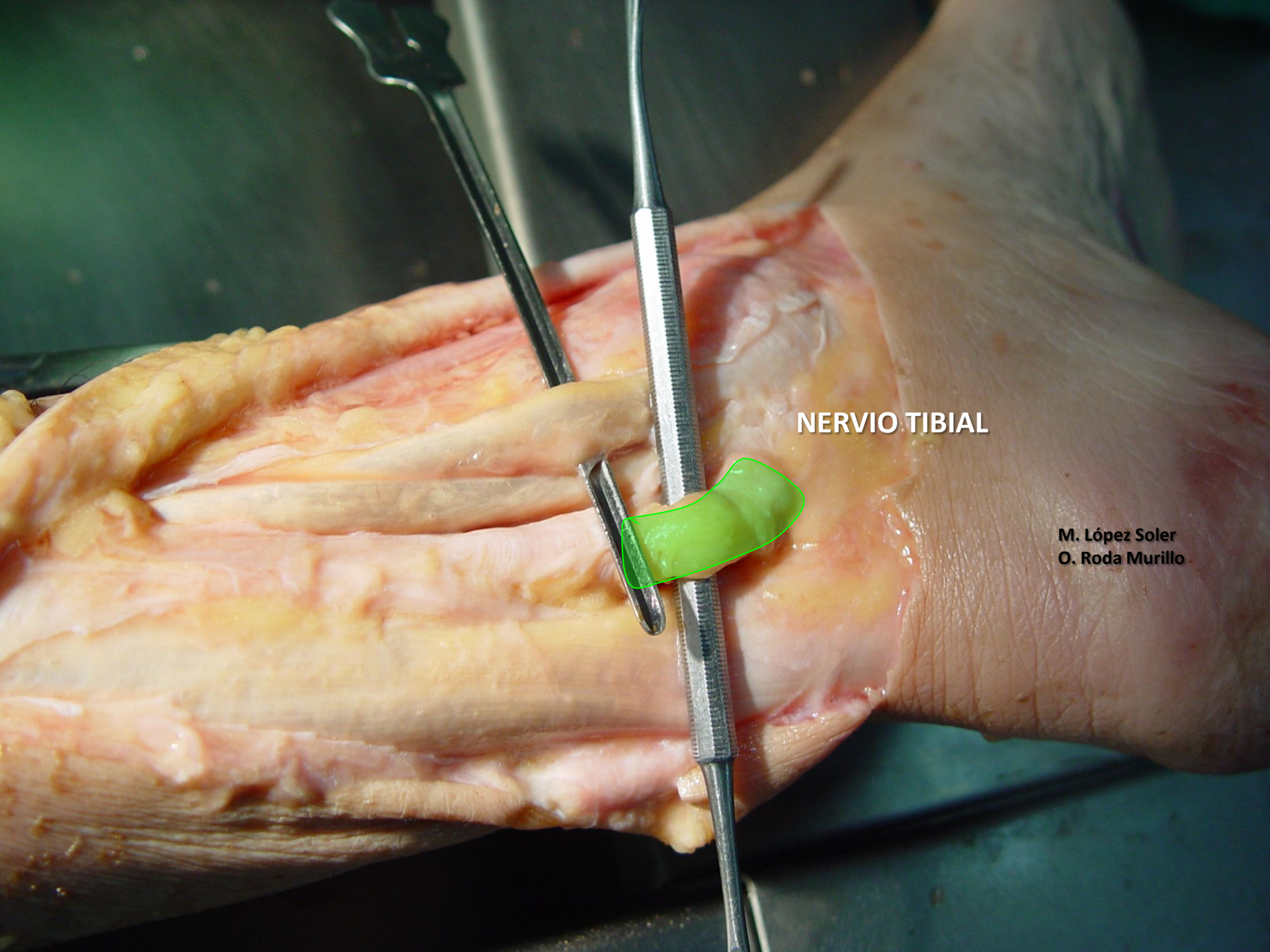


M. López Soler
O. Roda Murillo

**TENDÓN DEL MÚSCULO
FLEXOR LARGO DE LOS DEDOS**

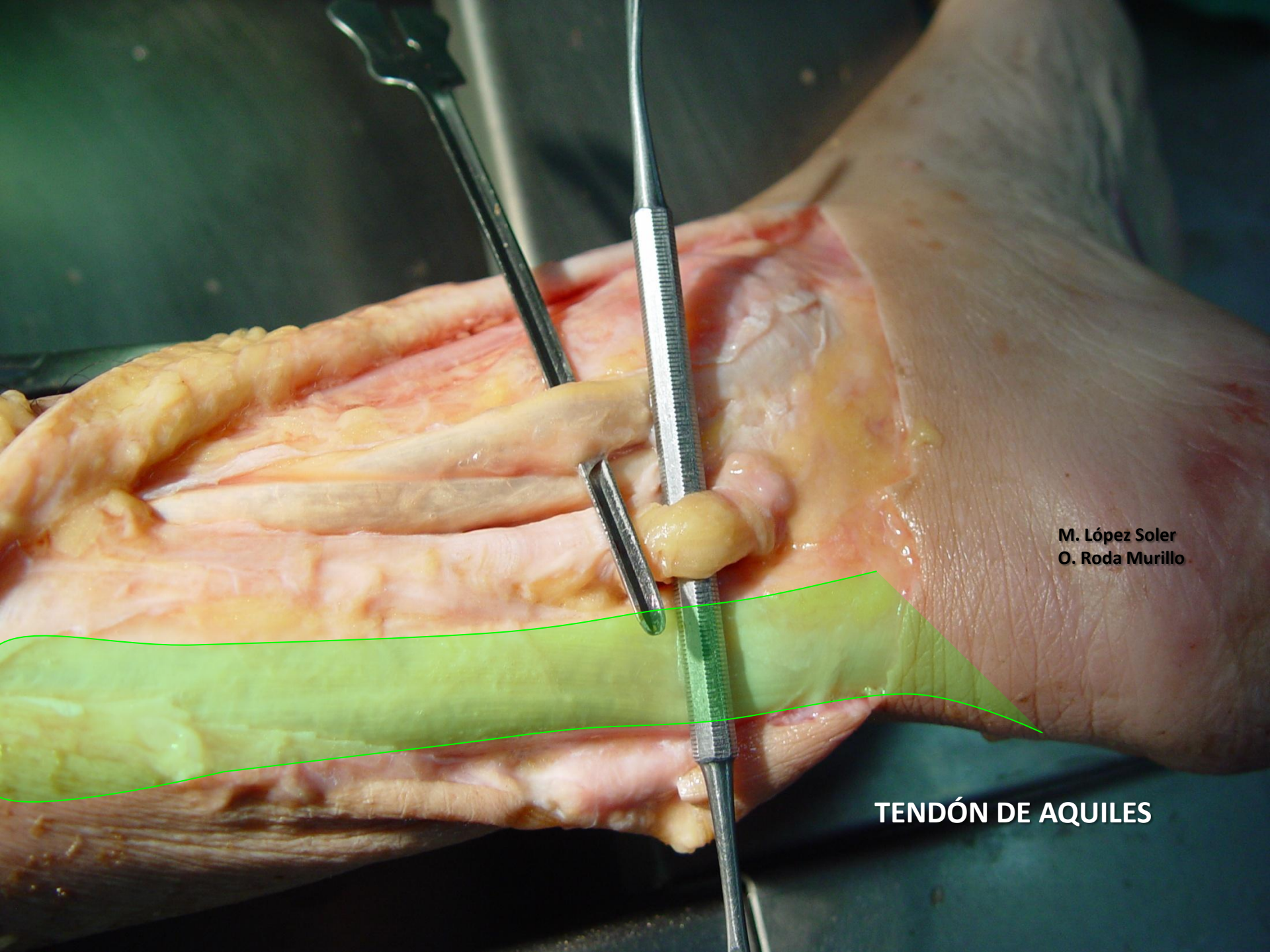

M. López Soler
O. Roda Murillo



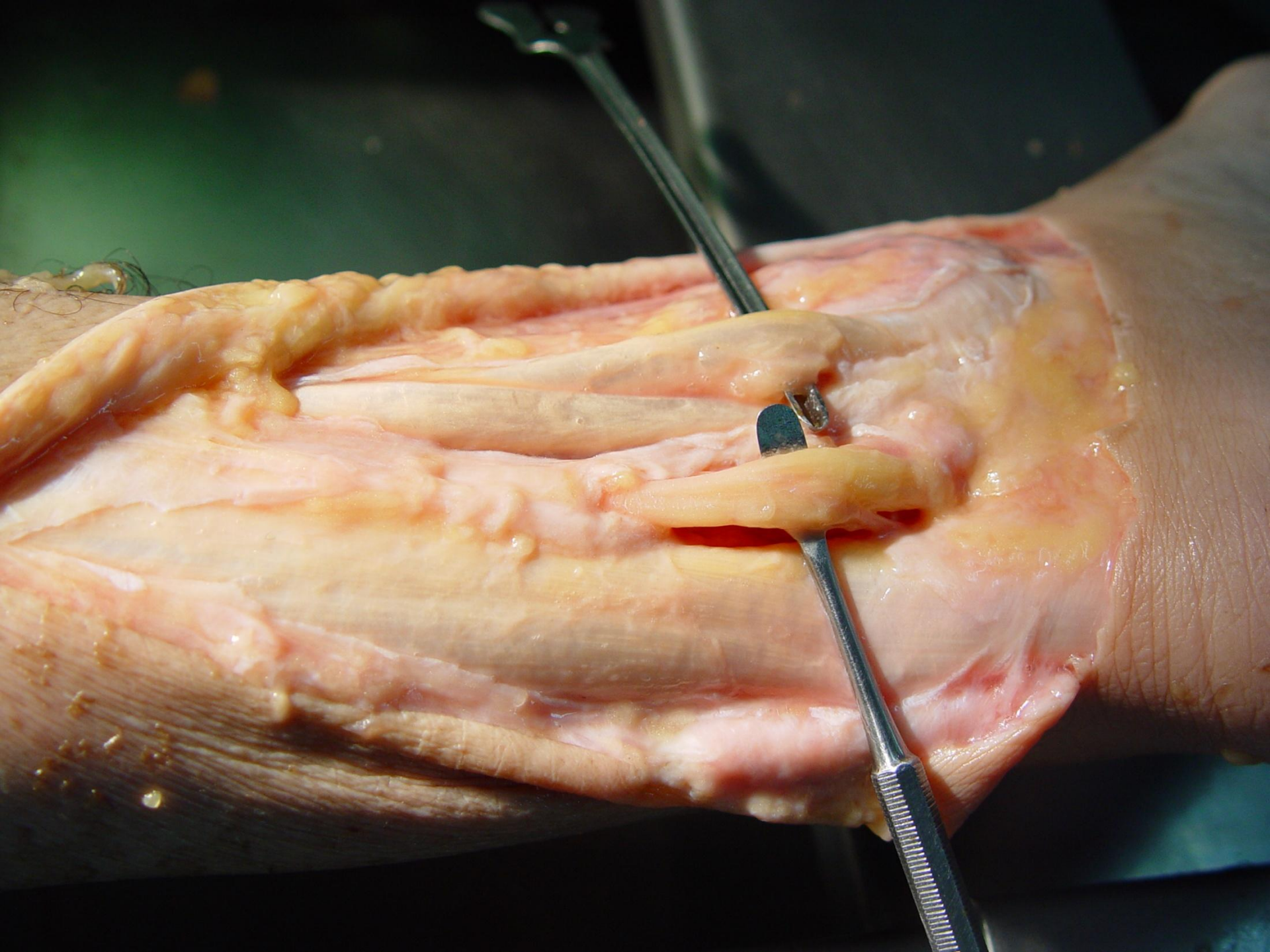
NERVIO TIBIAL

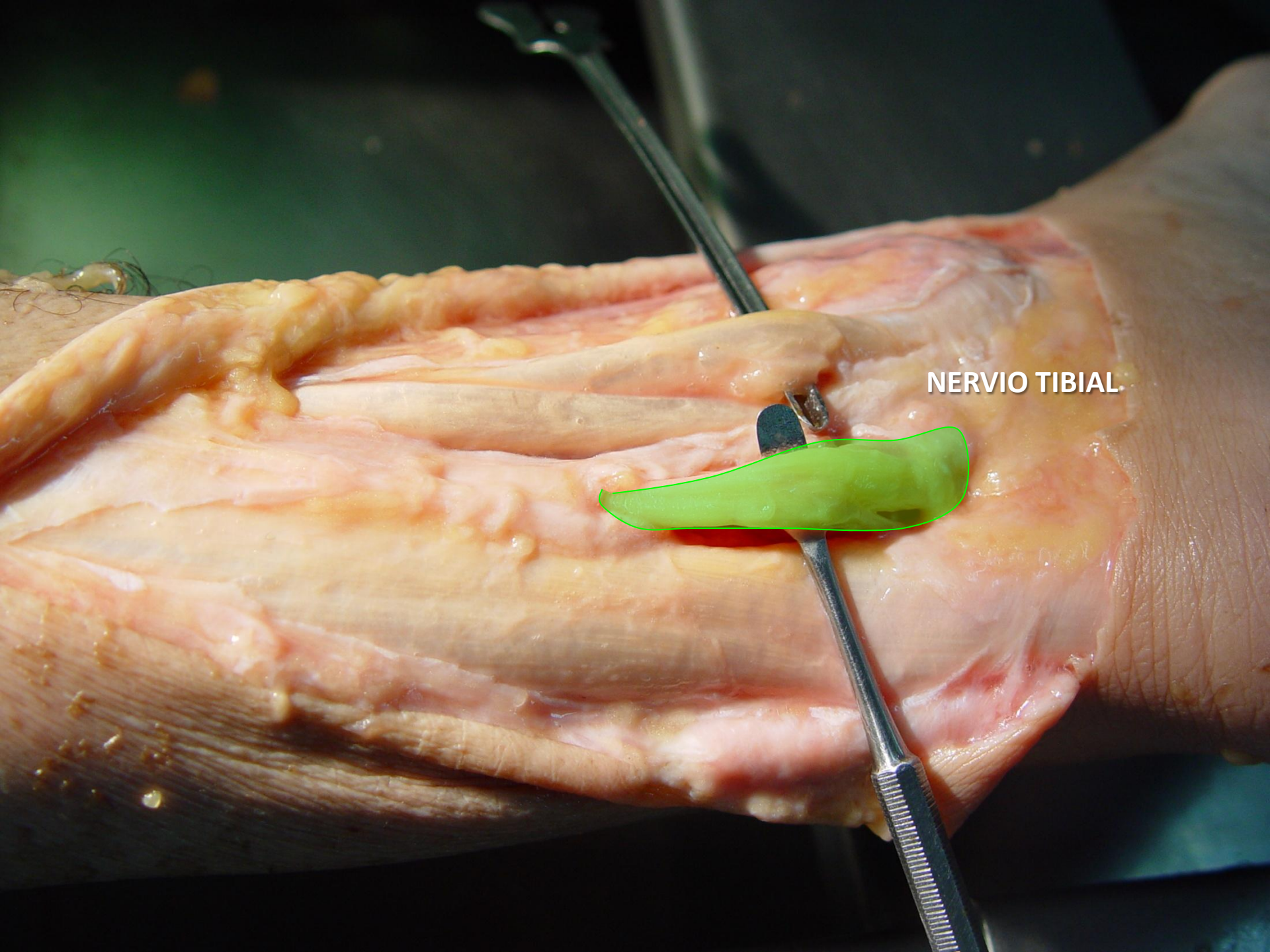
M. López Soler
O. Roda Murillo



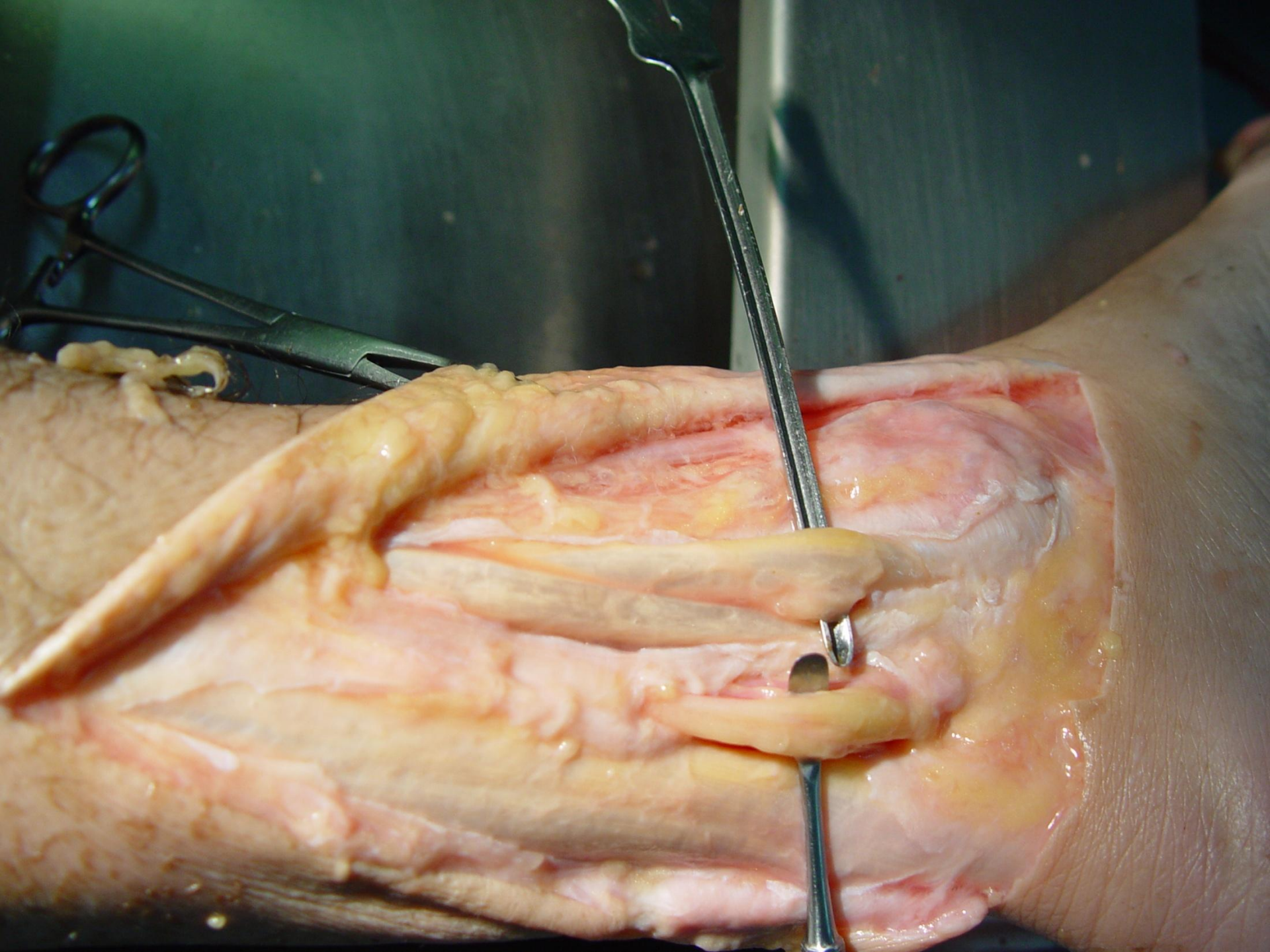M. López Soler
O. Roda Murillo

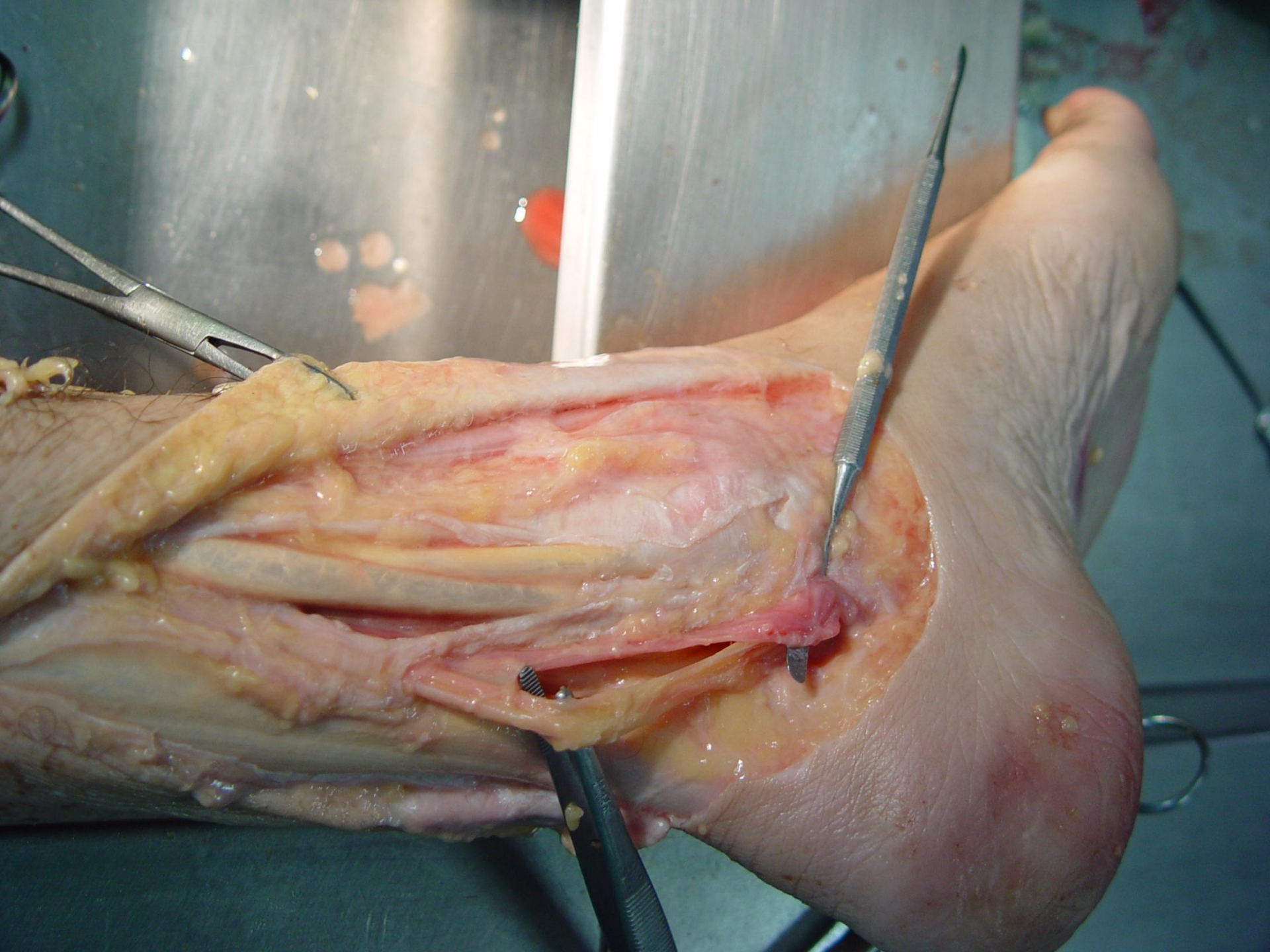
TENDÓN DE AQUILES

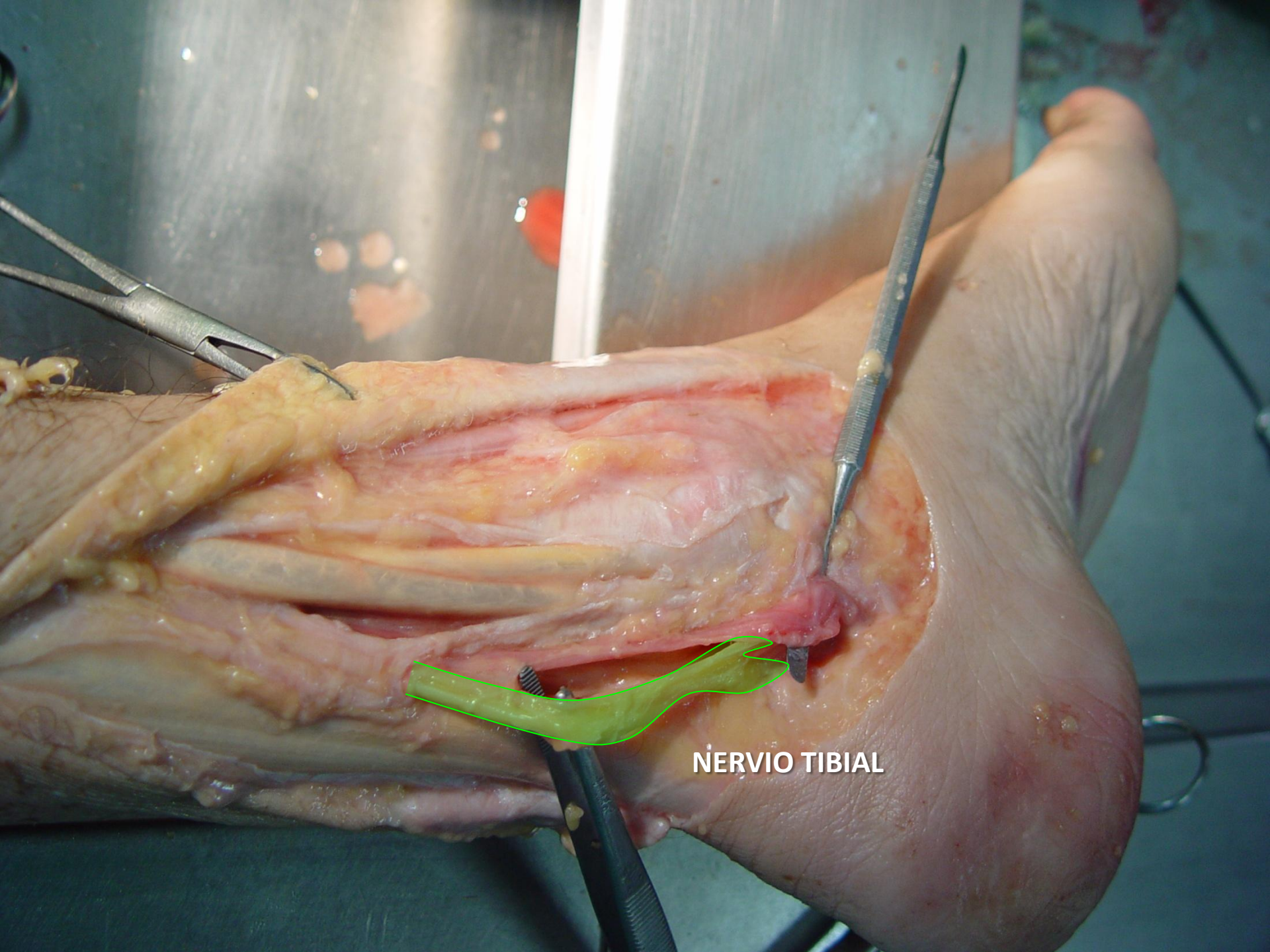




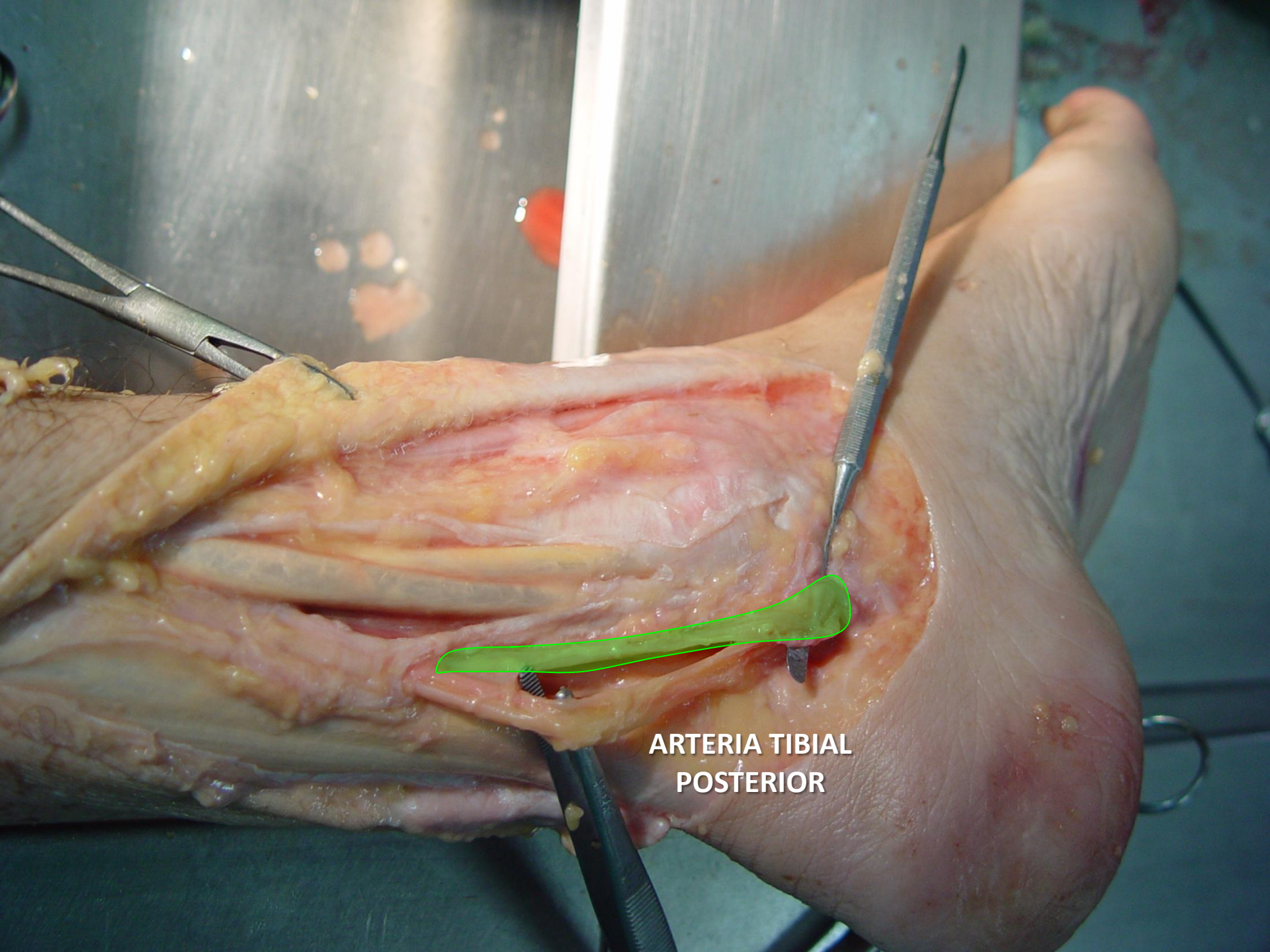NERVIO TIBIAL.



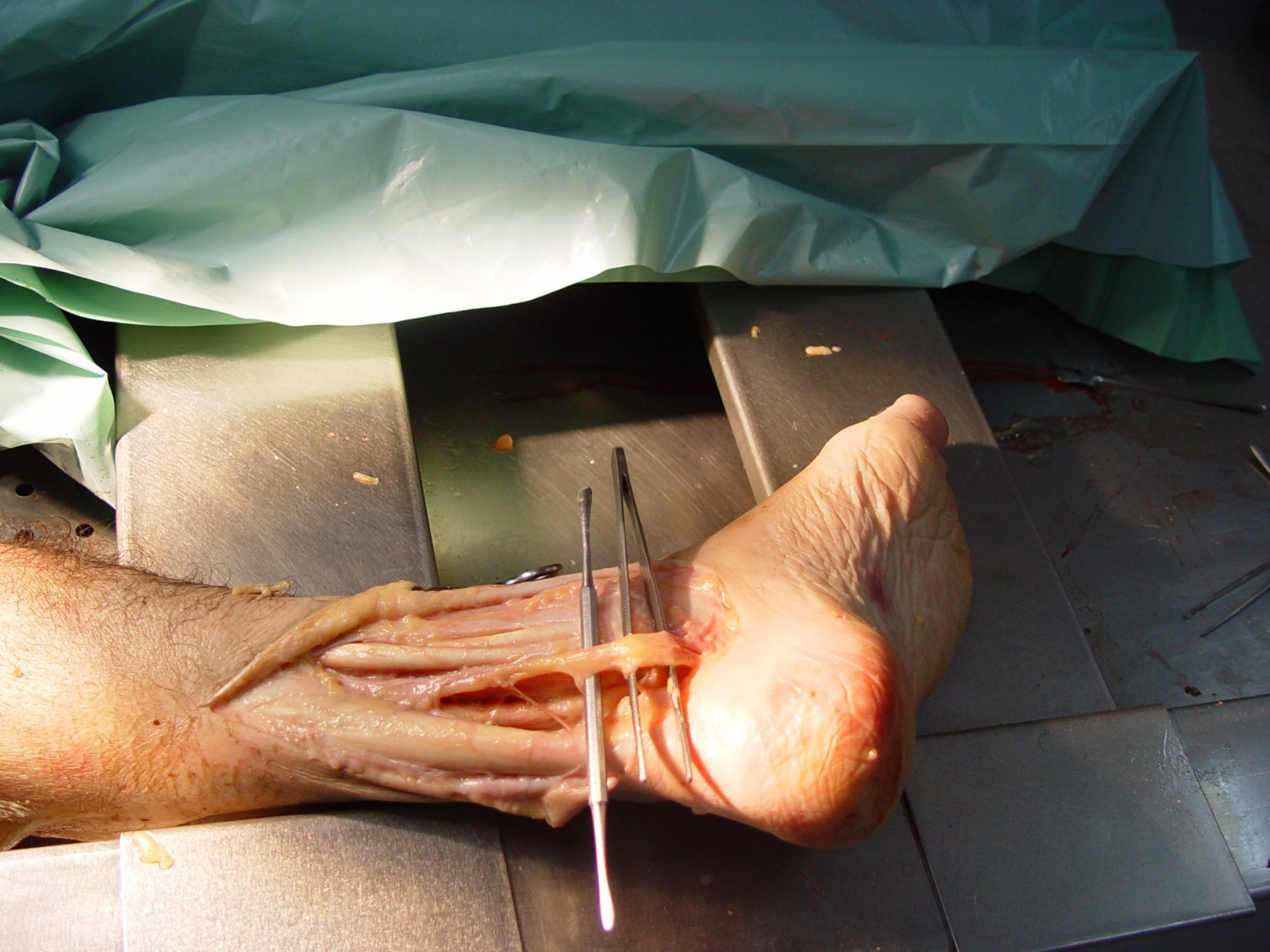


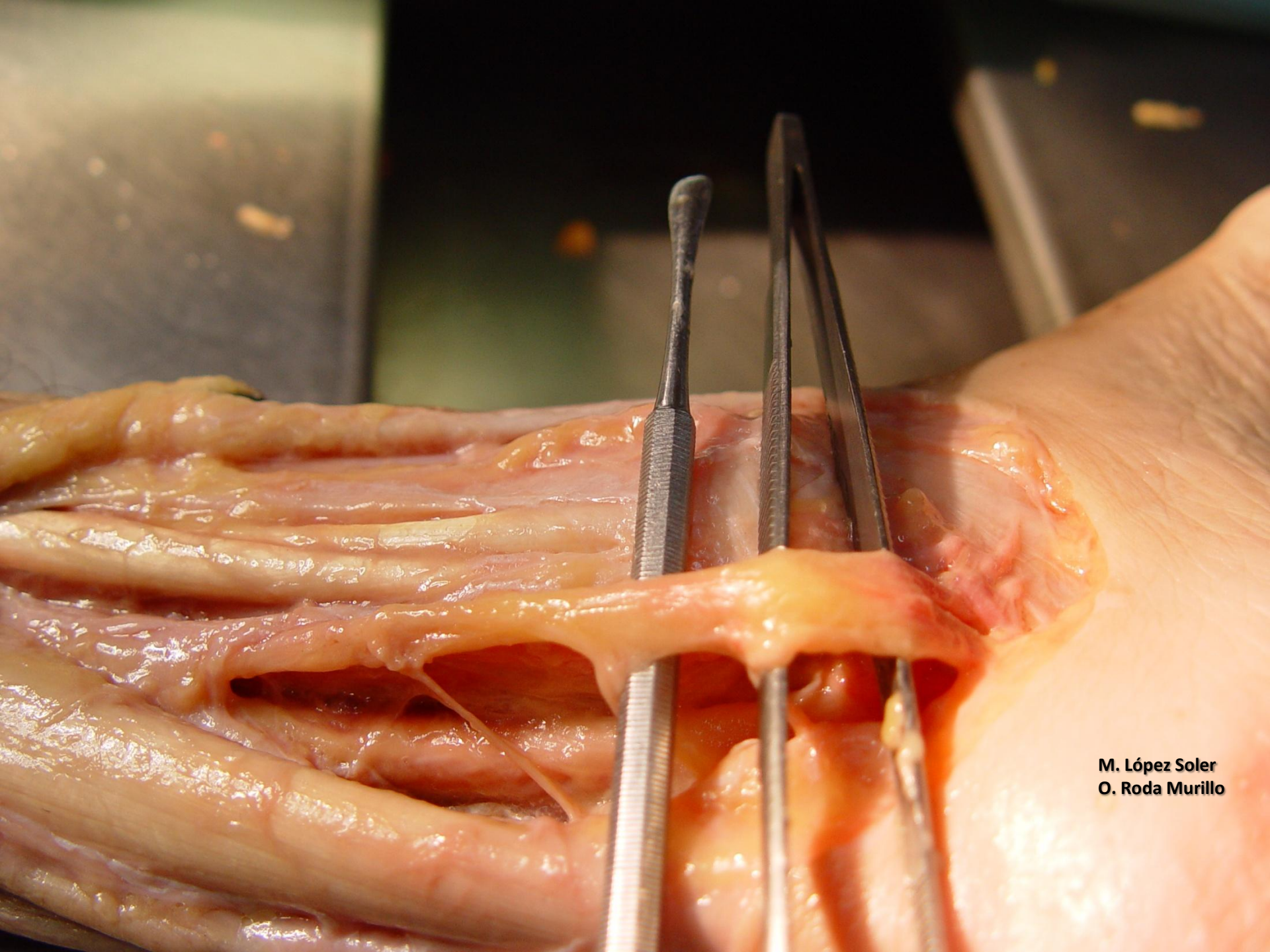


NERVIO TIBIAL



**ARTERIA TIBIAL
POSTERIOR**



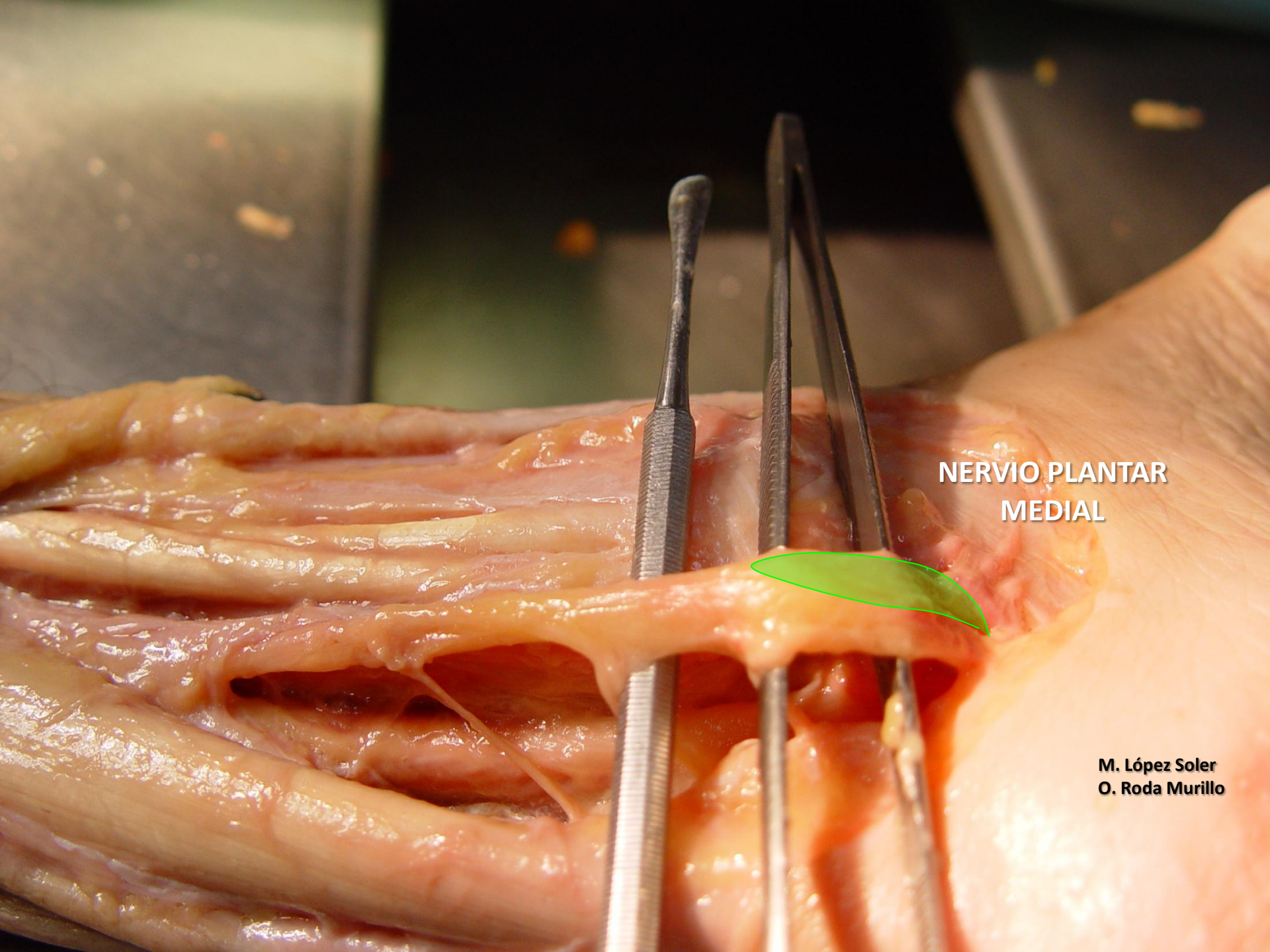


**M. López Soler
O. Roda Murillo**

An anatomical dissection of the tibial nerve. The nerve is shown as a long, pale, cord-like structure, highlighted with a green outline. It is surrounded by various tissues, including muscles and connective tissue. Surgical instruments, including a pair of forceps and a probe, are used to hold and examine the nerve. The background is dark, and the lighting is focused on the dissection area.

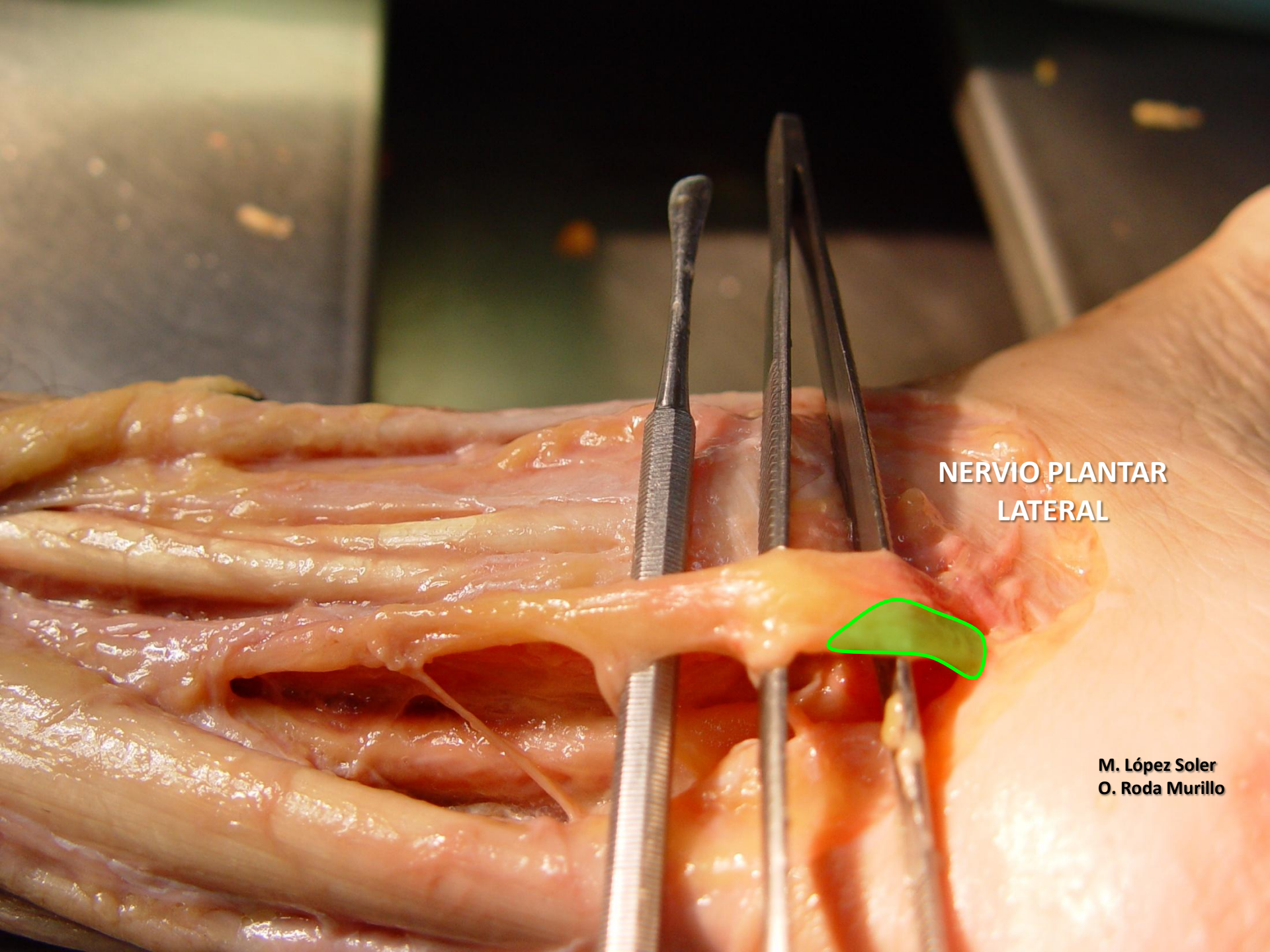
NERVIO TIBIAL

M. López Soler
O. Roda Murillo



**NERVIO PLANTAR
MEDIAL**

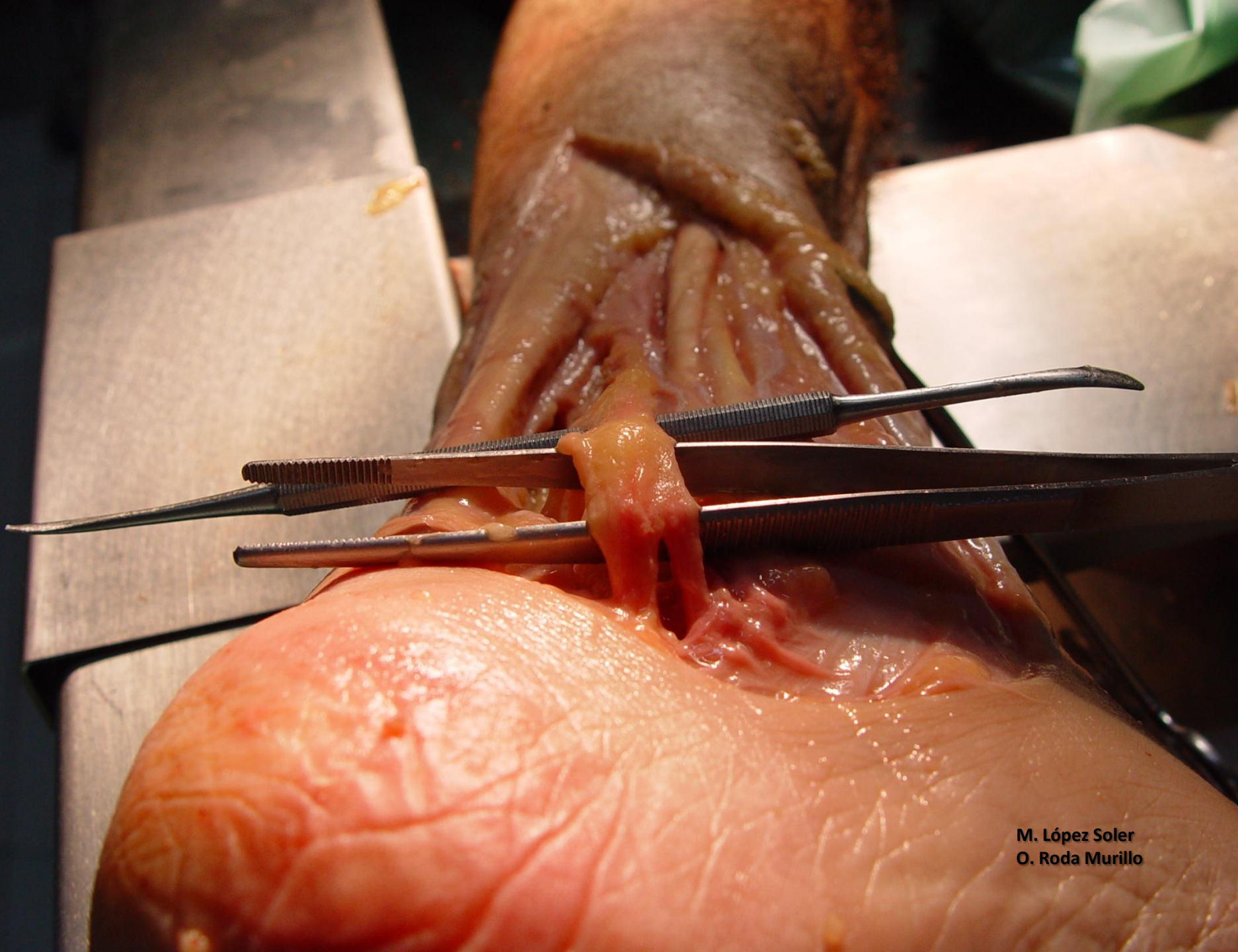
**M. López Soler
O. Roda Murillo**



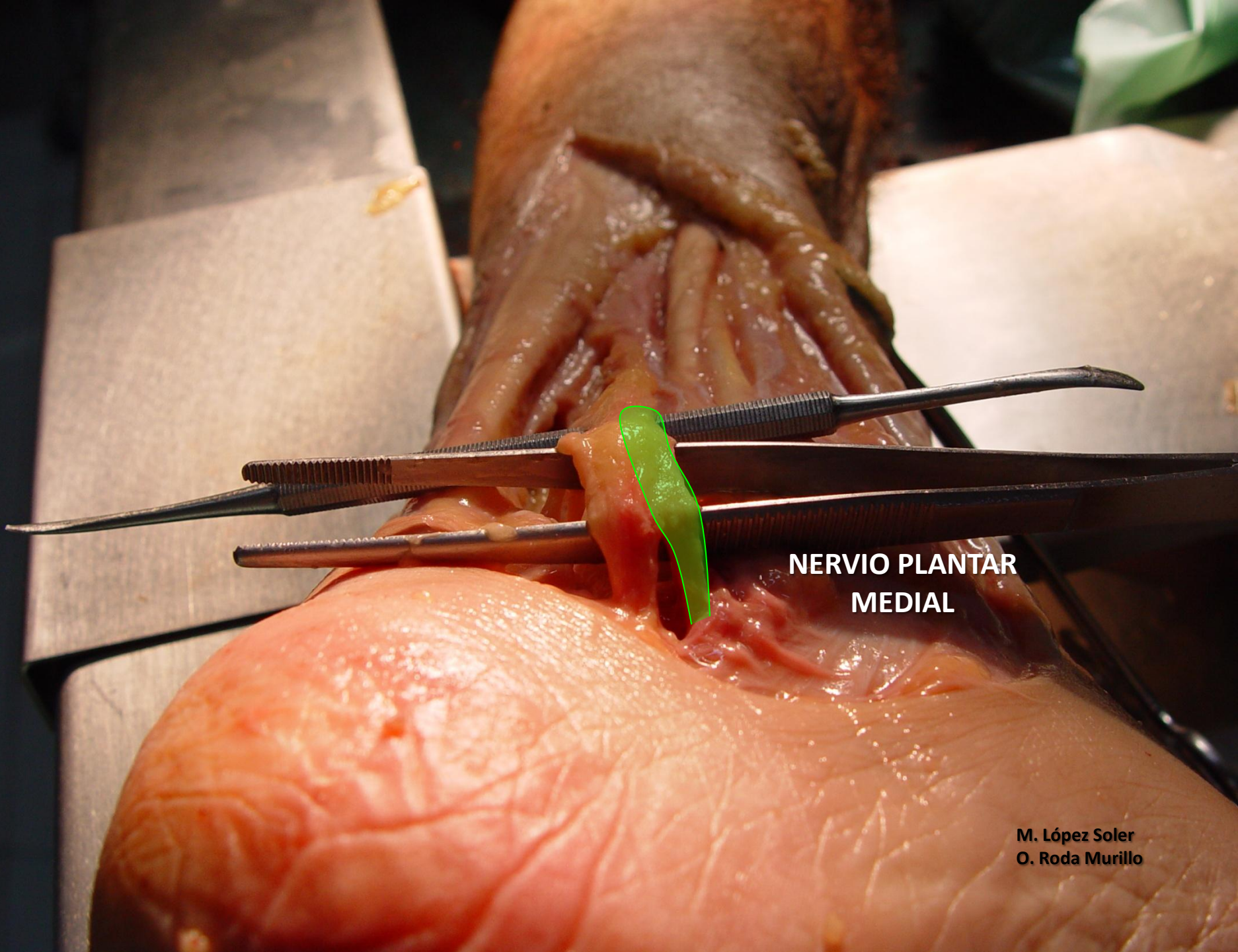
**NERVIO PLANTAR
LATERAL**



**M. López Soler
O. Roda Murillo**



M. López Soler
O. Roda Murillo



**NERVIO PLANTAR
MEDIAL**

**M. López Soler
O. Roda Murillo**

An anatomical dissection of a pig's foot, showing the lateral plantar nerve. The nerve is highlighted with a green outline. Several surgical instruments, including forceps and a scalpel, are used to hold and expose the nerve. The surrounding tissue is pinkish-red, and the skin is a lighter, textured color. The dissection is performed on a white surface, likely a surgical table or tray.

**NERVIO PLANTAR
LATERAL**

M. López Soler
O. Roda Murillo

M. López Soler
O. Roda Murillo

A detailed anatomical dissection of a pig's hand, showing the skeletal structure and surrounding soft tissues. The hand is held in a flexed position. Several surgical instruments are visible: a pair of forceps is holding a piece of yellowish, fatty tissue, and a pair of scissors is positioned nearby. The background is a dark, clinical setting with a white paper drape.

Fin